Endocrine Development

Hormone *from hormon (Gk) to set in motion, to urge on (E.H. Starling 1866-1927)*

Objectives

- Understanding of hormone types
- Focus on hypothalamus and pituitary development
- Understanding of endocrine gland development
- Understanding of endocrine developmental functions
- Brief understanding of molecular regulation and signalling mechanisms



Citation: The Developing Human: clinically oriented embryology 9th ed. Keith L. Moore, T.V.N. Persaud, Mark G. Torchia. Philadelphia, PA: Saunders, 2011.
Chapter 9 – Pharyngeal Apparatus, Face, and Neck
Chapter 12 - Urogenital System

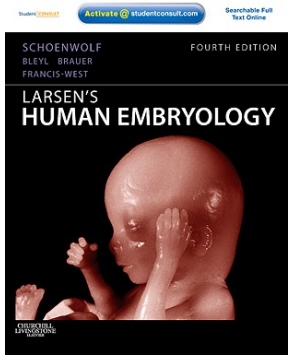

Citation: Larsen's human embryology 4th ed. Schoenwolf, Gary C; Larsen, William J, (William James). Philadelphia, PA : Elsevier/Churchill Livingstone, c2009.
Chapter 16 - Development of the Pharyngeal Apparatus and Face
Chapter 15 - Development of the Urogenital System

Nussey, S. and Whitehead, S. (2001). *Endocrinology - An Integrated Approach*. UK Oxford: BIOS Scientific Publishers. ISBN-10: 1-85996-252-1. Detailed Table of Contents | Bookshelf Link

- Chapter 1. Principles of endocrinology
- Chapter 2. The endocrine pancreas
- Chapter 3. The thyroid gland
- Chapter 4. The adrenal gland
- Chapter 5. The parathyroid glands and vitamin D
- Chapter 6. The gonad
- Chapter 7. The pituitary gland
- Chapter 8. Cardiovascular and renal endocrinology

Hormones

Produced by endocrine glands – ductless glands that secrete hormones into the blood

- **Amino acid derivatives** – noradrenaline (norepinephrin), adrenalin (epinephrin), thyroid hormone
- **Peptides and proteins** – Thyroid stimulating hormone, leutenising hormone, follicle stimulating hormone (HPG axis)
- **Steroids** – androgens, glucocorticoids (regulate inflammation), mineralocorticoids (salt and water balance)

All hormones act upon cells in different tissues and can be classified by the "distance" of their action, the classical description is that hormones are delivered by the blood.

- **Autocrine** - acts on self (extracellular fluid) – e.g. cytokines such as interleukin-1 in monocytes
- **Paracrine** - acts locally (extracellular fluid or blood) – e.g. fgf, Wnt, shh,
- **Endocrine** - acts by secretion into blood stream (endocrine organs are richly vascularized).

Hormone Receptors

- **cell surface** - modified amino acids, peptides, proteins – e.g. FSH receptor, G-protein coupled receptor
- **intracellular cytoplasmic/nuclear** – steroids – androgen receptor, Nuclear receptor subfamily 3, C4 (NR3C4)

The pineal is a cone-shaped diverticulum of the roof of the diencephalon

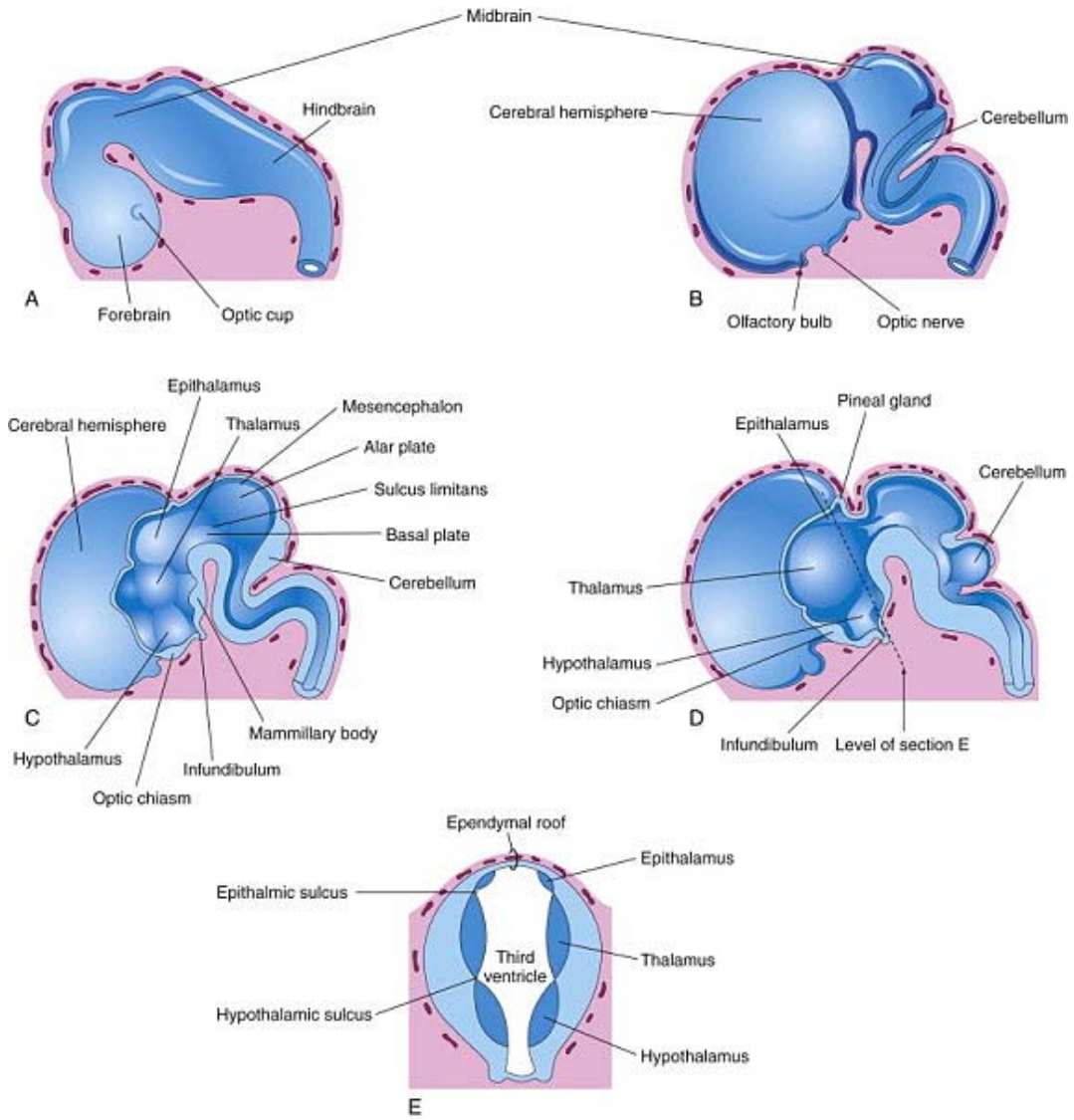

- Pine–cone shaped
- Secretes melatonin
- Produced by pinealocytes
- Input from visual system
- Has a role in the inhibition of gonadotrophic hormones - when it is damaged, premature puberty ensues.
- Diminishes after puberty
- Not isolated by the blood brain barrier – rich vasculature

Position of the adult pineal gland

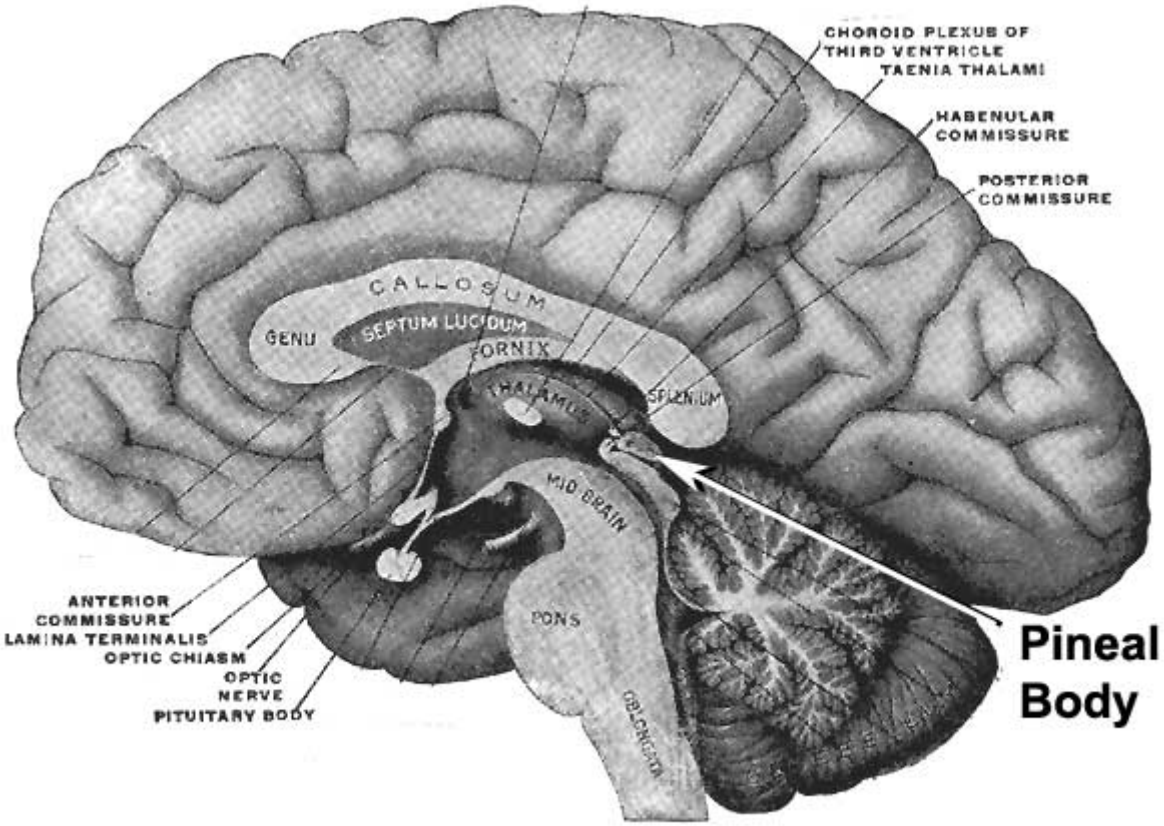

The hypothalamus – controls anterior pituitary and forms the posterior pituitary

Hormones - Thyrotrophin releasing hormone (TRH), Corticotrophin releasing hormone (CRH), Arginine vasopressin (AVP), Gonadotrophin releasing hormone (GnRH), Growth hormone releasing hormone (GHRH), Somatostatin, Prolactin relasing factor (PRF), Dopamine

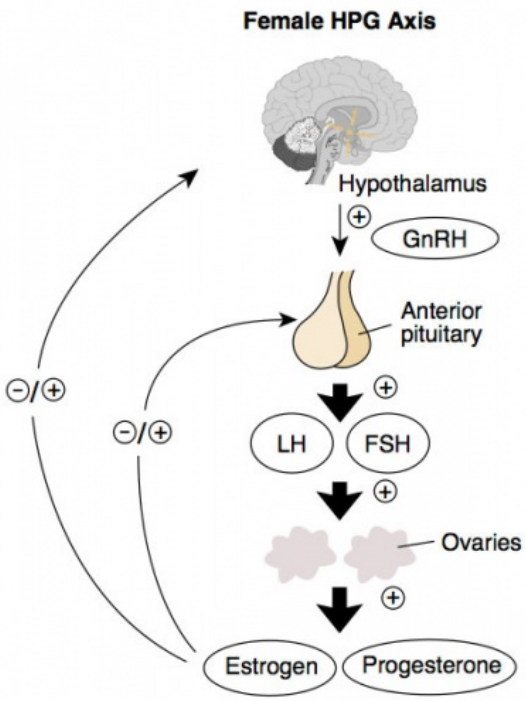

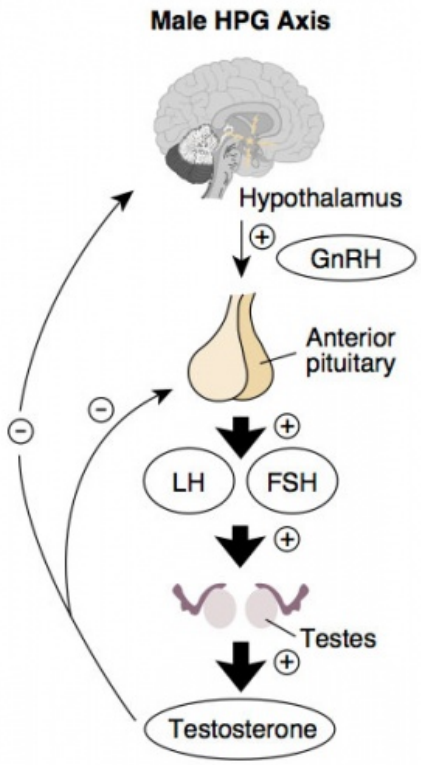

The hypothalamus – controls anterior pituitary and forms the posterior pituitary

Hormones - Thyrotrophin releasing hormone (TRH), Corticotrophin releasing hormone (CRH), Arginine vasopressin (AVP), Gonadotrophin releasing hormone (GnRH), Growth hormone releasing hormone (GHRH), Somatostatin, Prolactin relasing factor (PRF), Dopamine

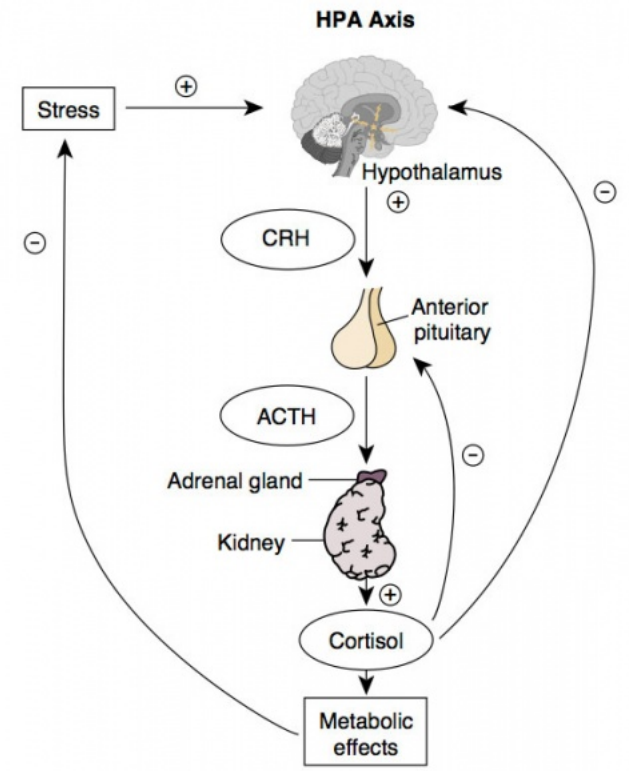

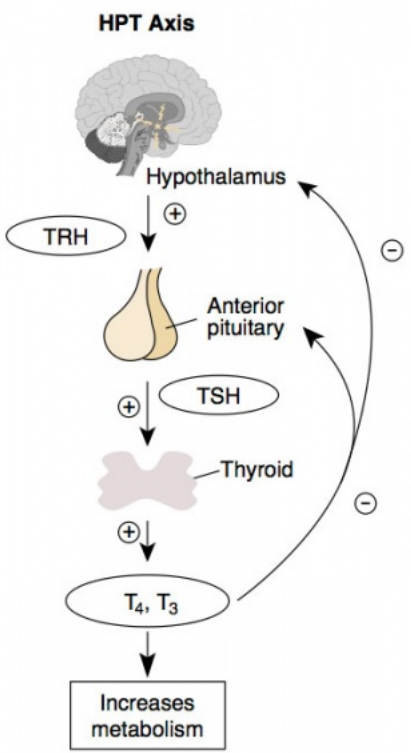

The nuclei of the hypothalamus

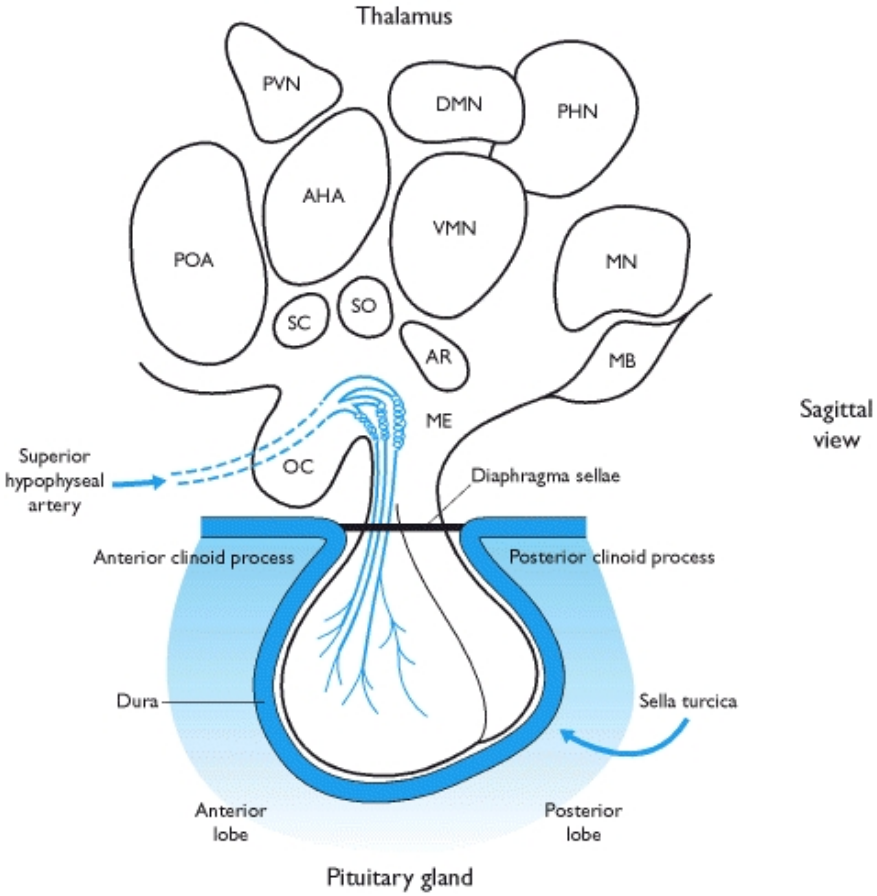

Endocrinology: An Integrated Approach.
Nussey S, Whitehead S.
Oxford: BIOS Scientific Publishers; 2001

Abbreviations: AHA, anterior hypothalamic area; AR, arcuate nucleus; DMN, dorsomedial nucleus; MB, mammillary body; ME, median eminence; MN, medial nucleus; OC, optic chiasm; PHN, posterior hypothalamic nucleus; POA, preoptic area; PVN, paraventricular nucleus; SCN, suprachiasmatic nucleus; SO, supraoptic nucleus; VMN, ventromedial nucleus

Paraventricular and supraoptic nuclei
- regulate water balance
- produce ADH and oxytocin
- destruction causes diabetes insipidus
- paraventricular nucleus projects to autonomic nuclei of brainstem and spinal cord

Anterior nucleus
- thermal regulation (dissipation of heat)
- stimulates parasympathetic NS
- destruction results in hyperthermia

Preoptic area
- contains sexually dimorphic nucleus
- regulates release of gonadotropic hormones

Suprachiasmatic nucleus
- receives input from retina
- controls circadian rhythms

Dorsomedial nucleus
- stimulation results in obesity and savage behavior

Posterior nucleus
- thermal regulation (conservation of heat)
- destruction results in inability to thermoregulate
- stimulates the sympathetic NS

Lateral nucleus
- stimulation induces eating
- destruction results in starvation

Mammillary body
- receives input from hippocampal formation via fornix
- projects to anterior nucleus of thalamus
- contains hemorrhagic lesions in Wernicke's encephalopathy

Ventromedial nucleus
- satiety center
- destruction results in obesity and savage behavior

Arcuate nucleus
- produces hypothalamic releasing factors
- contains DOPA-ergic neurons that inhibit prolactin release

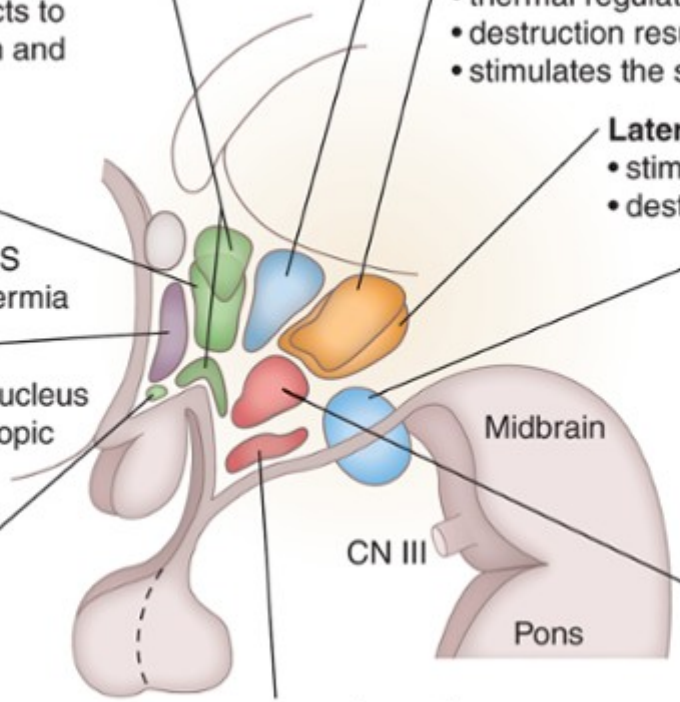

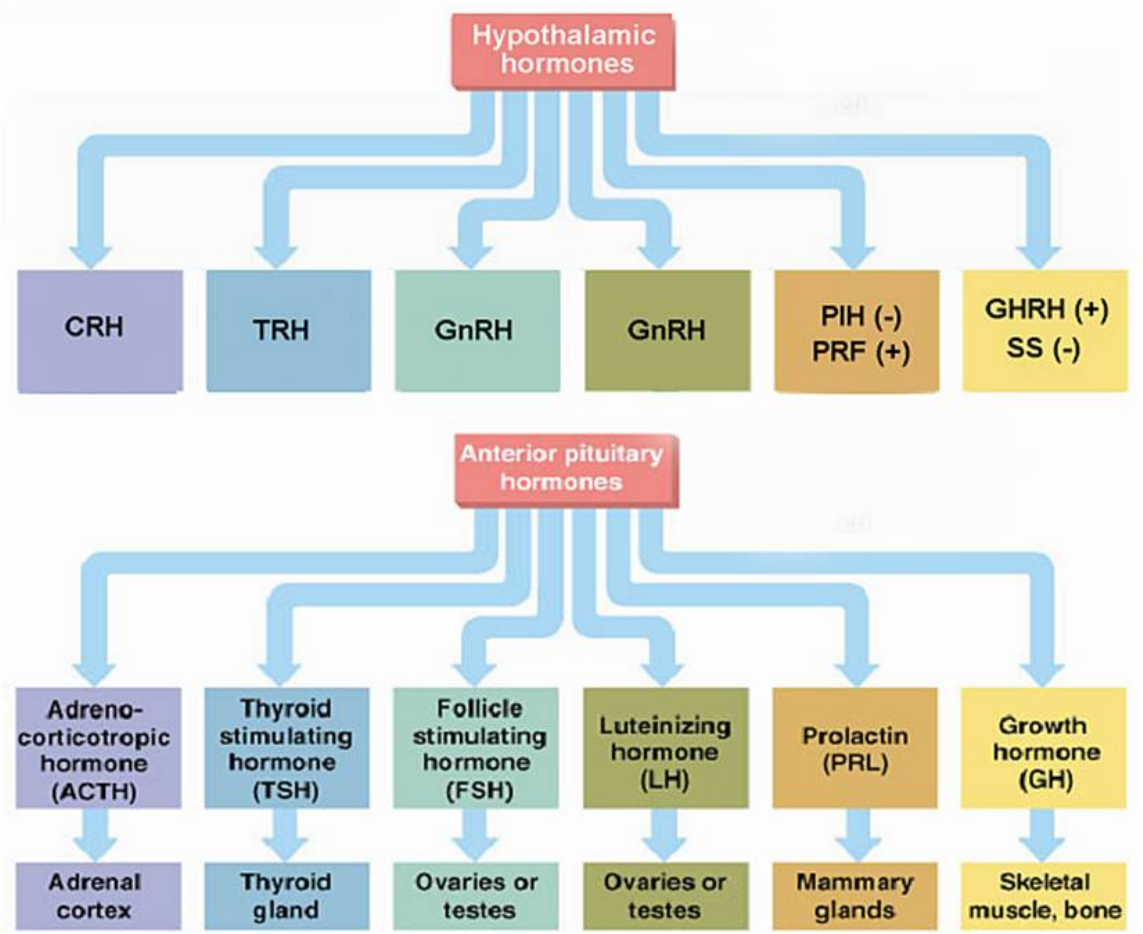
Hypothalamic hormones
CRH
TRH
GnRH
GnRH
PIH (-)
PRF (+)
GHRH (+)
SS (-)
Anterior pituitary hormones
Adreno-corticotropic hormone (ACTH)
Thyroid stimulating hormone (TSH)
Follicle stimulating hormone (FSH)
Luteinizing hormone (LH)
Prolactin (PRL)
Growth hormone (GH)
Adrenal cortex
Thyroid gland
Ovaries or testes
Ovaries or testes
Mammary glands
Skeletal muscle, bone

Pituitary development movie – Interaction between the floor of the diencephalon and the ectodermal roof of the stomadeum

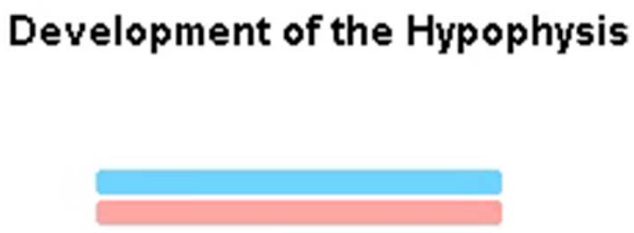

Rathke's pouch – the hypophysial diverticulum - forms the anterior lobe evident at 4-5 weeks

The downgrowth of the neuroectoderm - the neurohypophysial diverticulum forms the posterior lobe

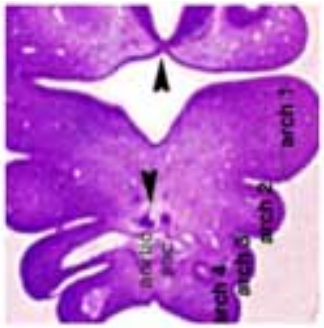

Rathke's Pouch
And Thyroid cells

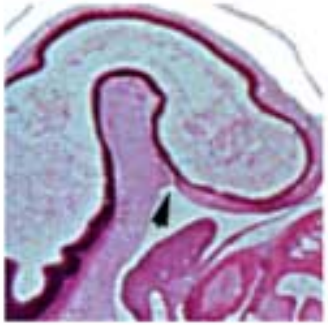

Rathke's Pouch

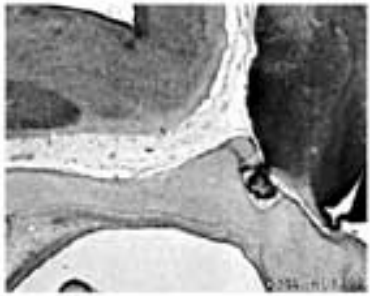

Fetal Pituitary

Pituitary development late

Connection with the oral cavity is lost as the sphenoid bone develops as part of the chondocranium at the base of the skull. The pituitary becomes encased in the **sella turcica** (turkish saddle)

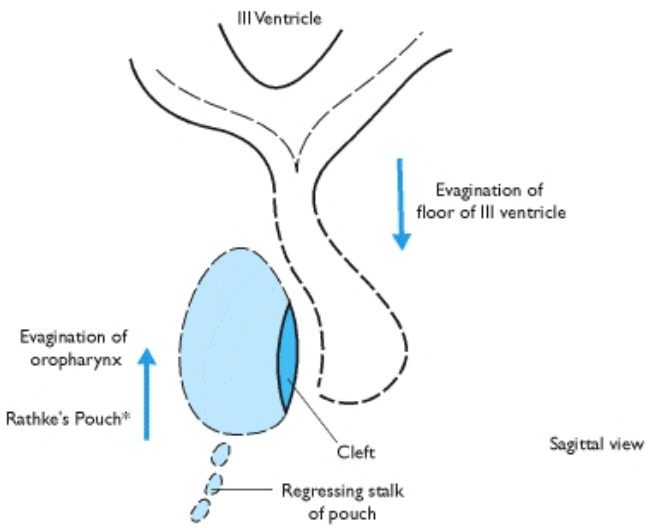

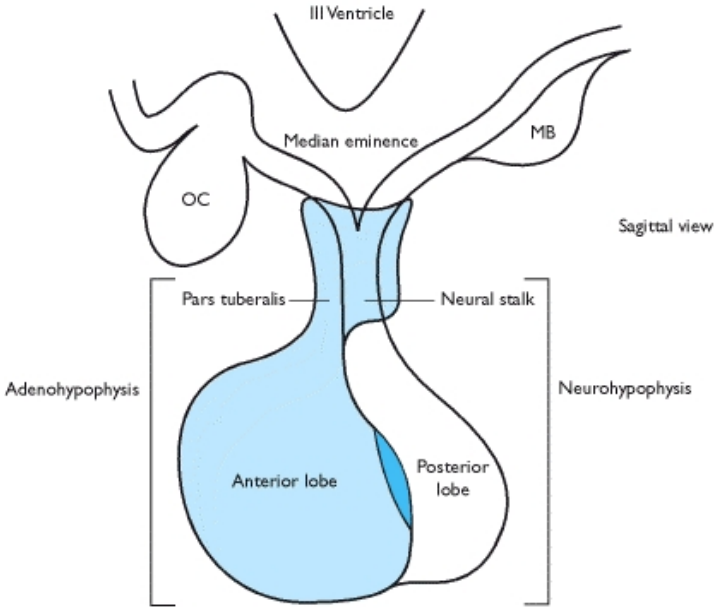

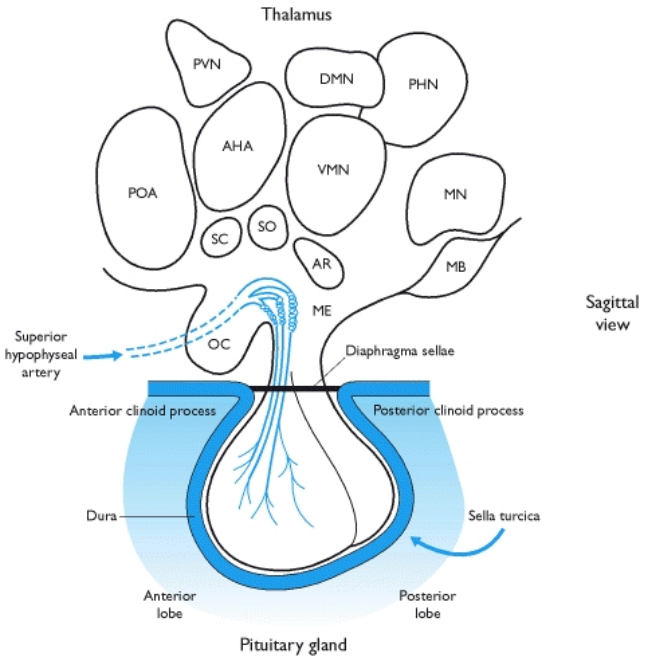

Pituitary development timeline

Week 4 - hypophysial pouch, Rathke's pouch, diverticulum from roof
Week 5 - elongation, contacts infundibulum, diverticulum of diencephalon
Week 6 - connecting stalk between pouch and oral cavity degenerates
Week 8 - basophilic staining cells appear
Week 9 - acidophilic staining cells appear
Week 10 - growth hormone and ACTH detectable
Week 16 - adenohypophysis fully differentiated and TSH increases to peak at 22 weeks
Week 20 to 24 - growth hormone levels peak, then decline
Birth - second TSH surge and decreases postnatal

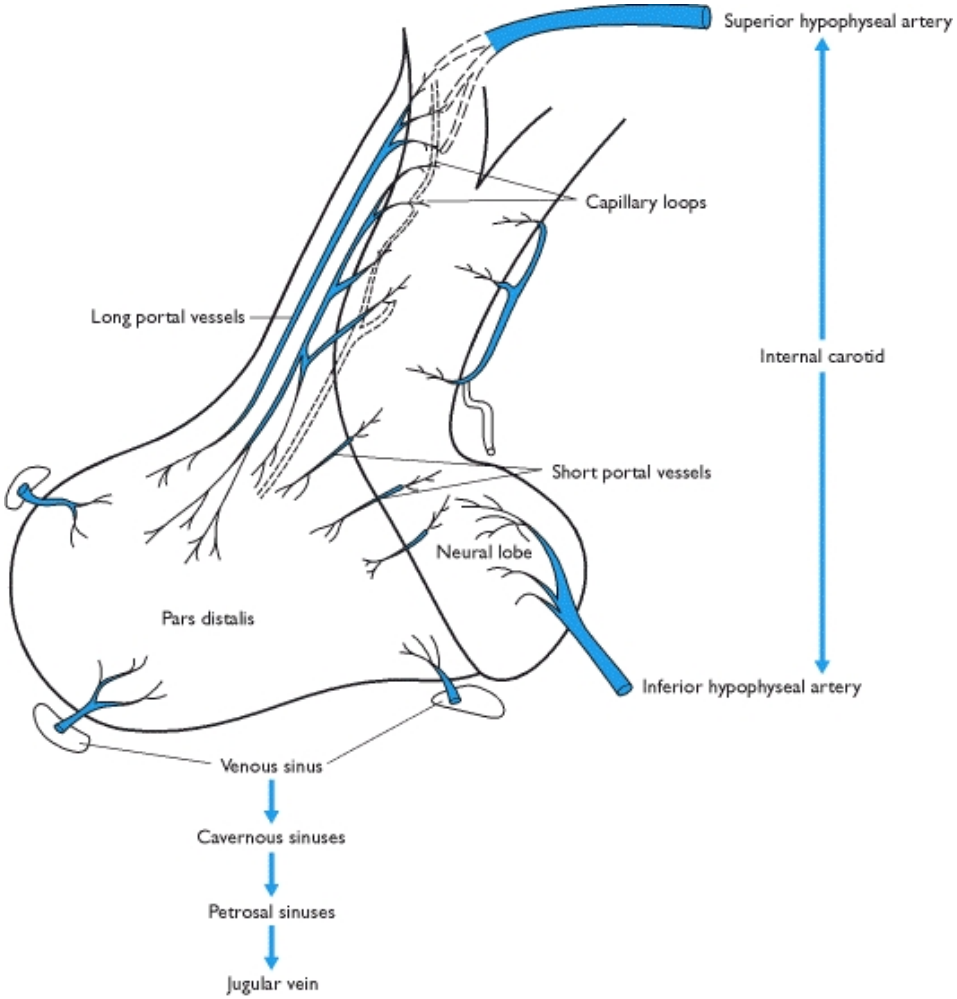

The vascular system of the pituitary

The pituitary gland maintains connections with the brain but sits outside of the blood brain barrier.

The pituitary has one of the richest blood supplies of anywhere in the body.

The posterior lobe is supplied by the inferior hypophyseal artery

The anterior lobe is supplied by the superior hypophyseal artery

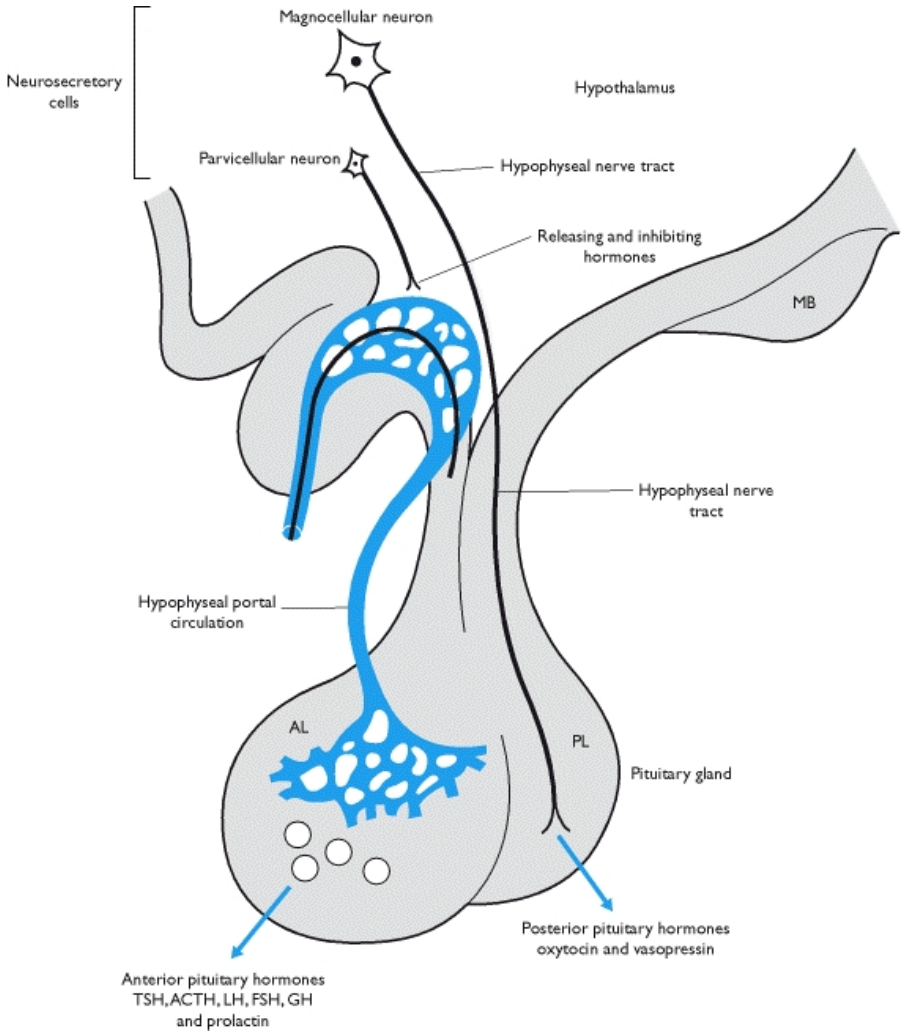

The vascular system of the pituitary

The long portal vessels of the superior hypophyseal artery forms the basis of the hypothalamo-hypophyseal portal system.

Inhibitory or stimulating peptides are released from the median eminence and quickly transported to the anterior pituitary.

Oxytocin and vasopressin are secreted by the magnocellular neurosecretory cells that have axonal projections into the posterior pituitary

Induction of pituitary development in the mouse

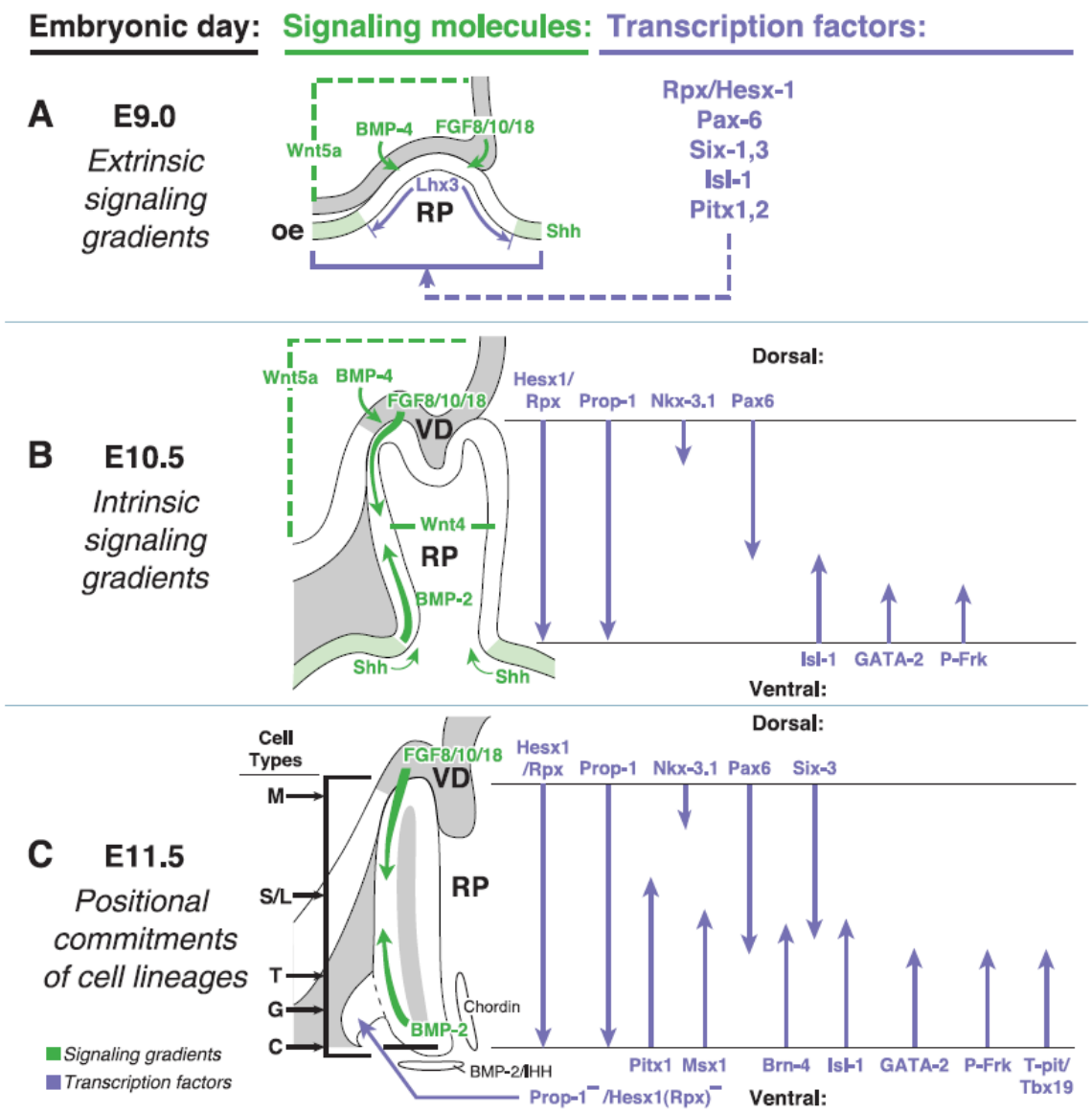

Differentiation of the six mature endocrine cell types of the anterior pituitary is determined by the action of a cascade of transcription factors

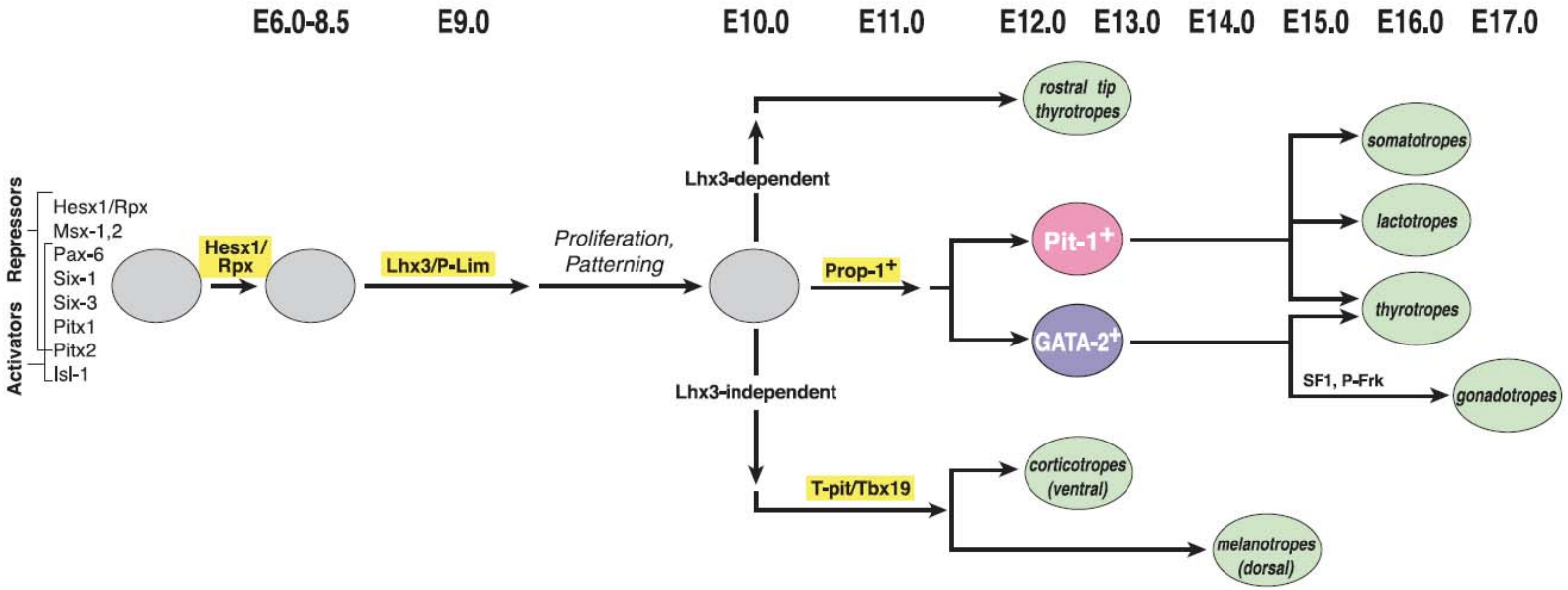

Thyroid development

Functions from week 10, required for neural development, stimulates metabolism (protein, carbohydrate, lipid), reduced/absence = cretinism

Hormones - (amino acid derivatives) Thyroxine (T4), Triiodothyronine (T3)

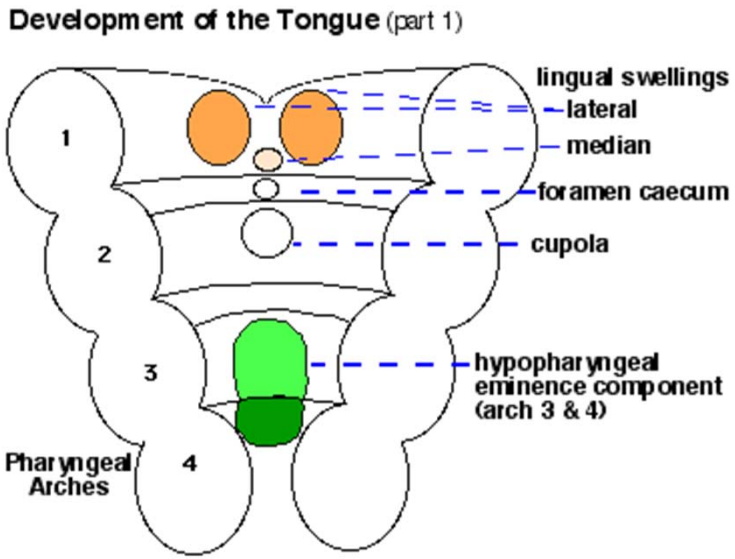

Begins at 24 days as endodermal thickening which outpouches to form the **thyroid primordium**. As the tongue and thyroid grows the thyroid descends into the neck ventral to the hyoid bone and laryngeal cartilages. The duct that is left behind – **the thyroglossal duct** eventually disappears

Stage 13 – week 4-5

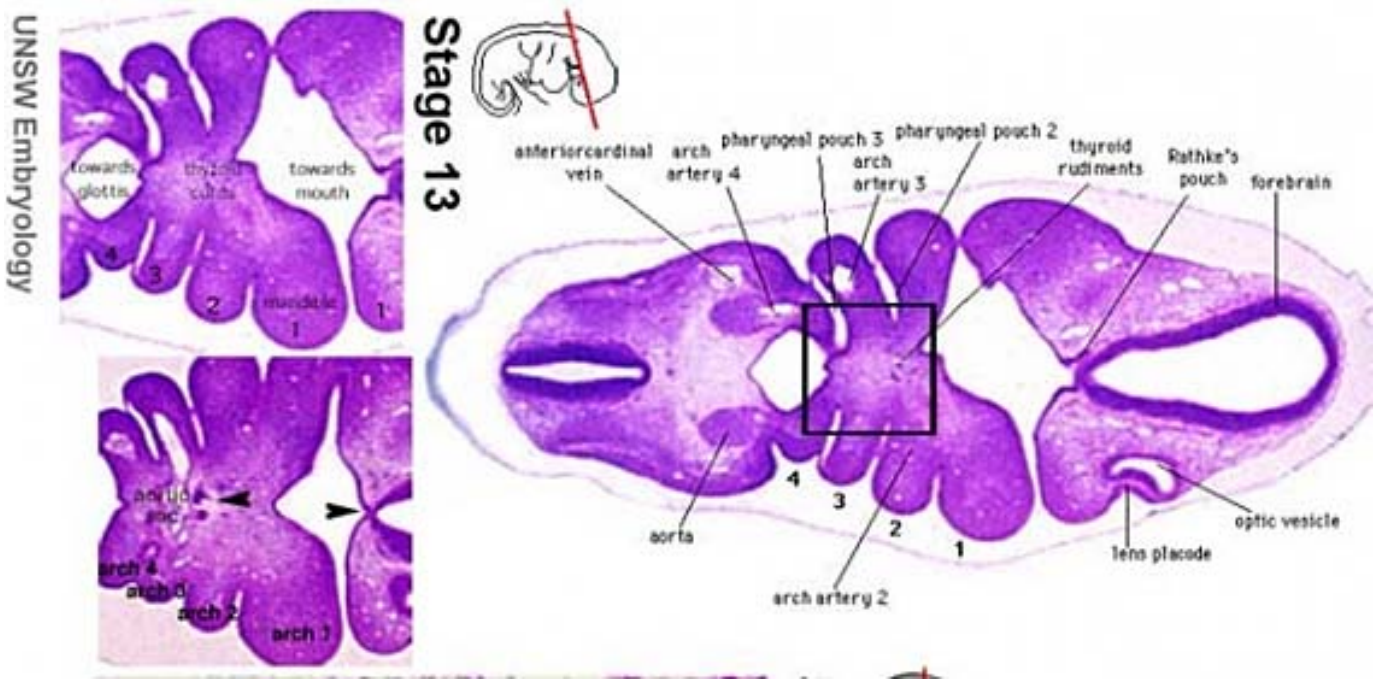

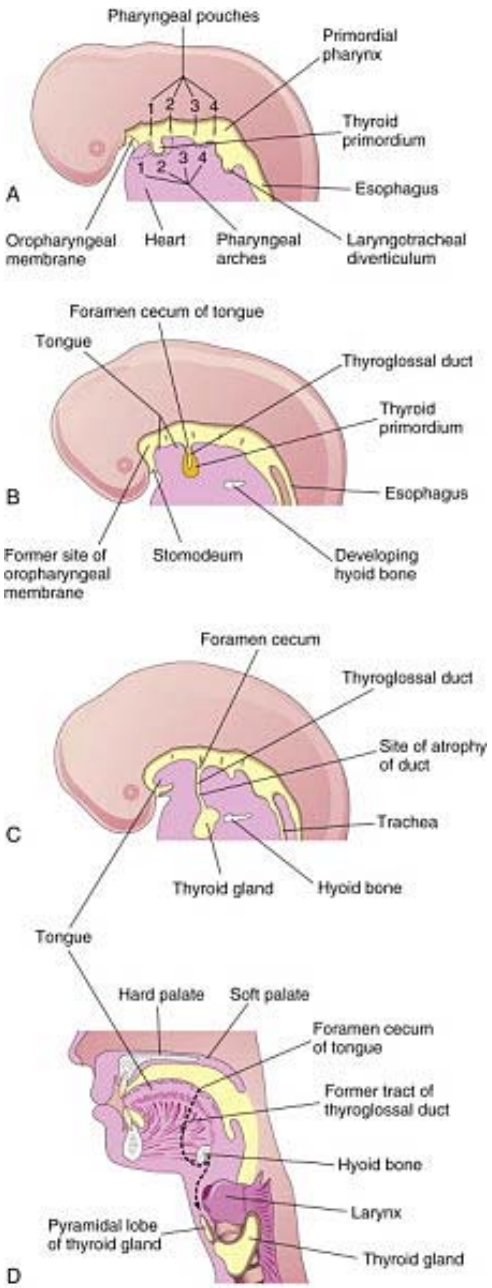

Sagittal view of thyroid development in the context of the developing tongue

Floor of mouth/Tongue

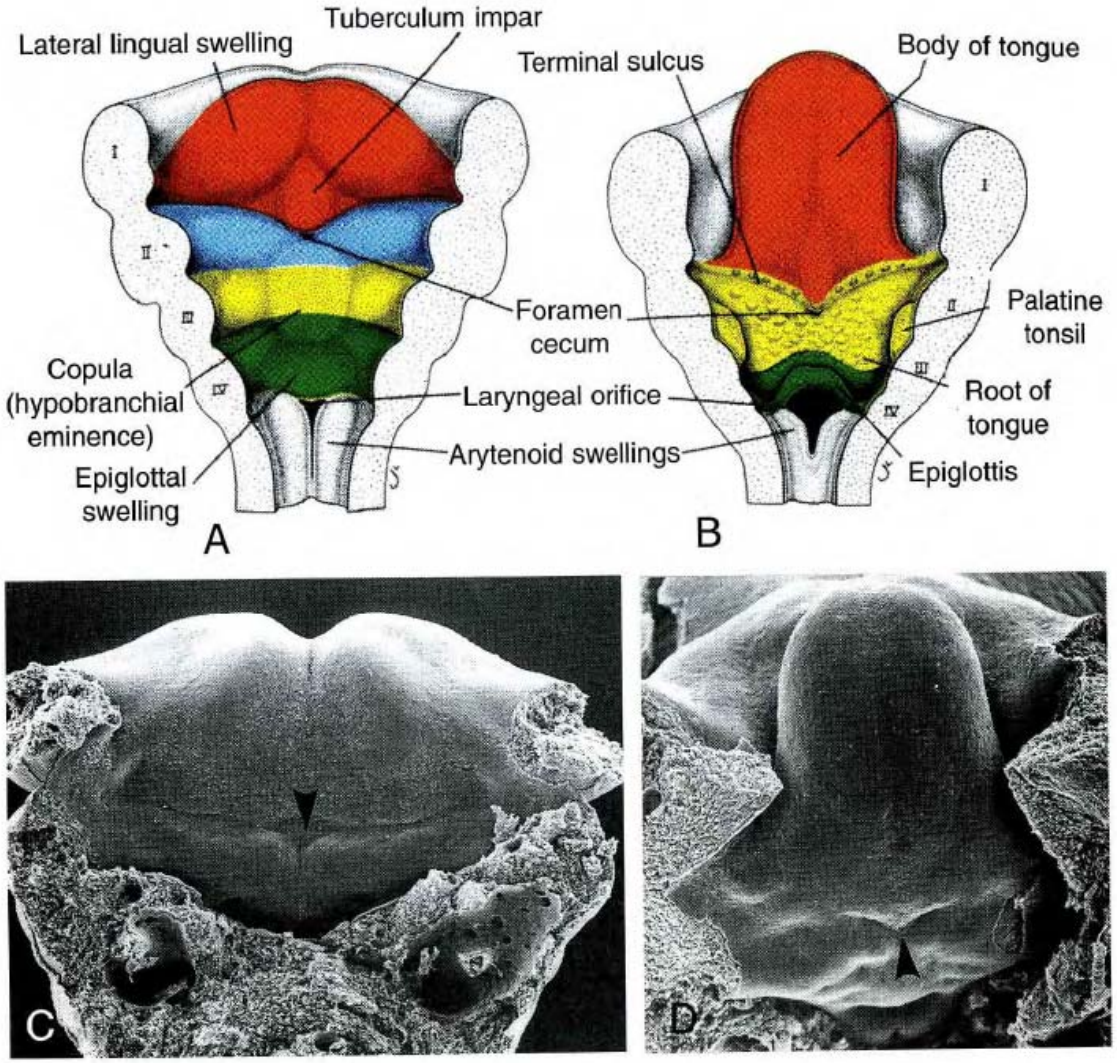

Thyroid gland migration and thyroglossal cysts

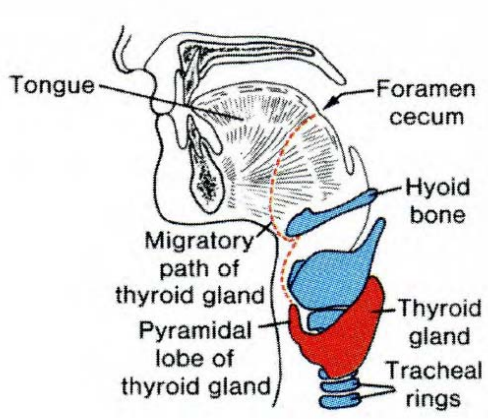

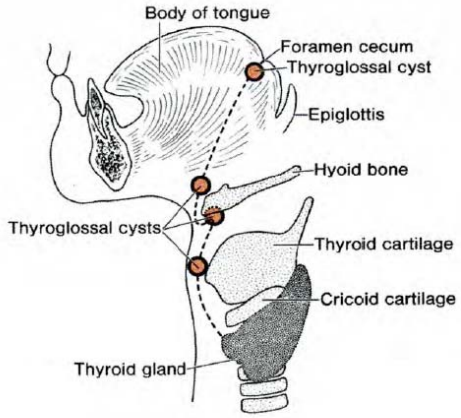

- thyroid median endodermal thickening in the floor of pharynx between the tuberculum impar and the copula
- This outpouches to form the thyroid diverticulum
- tongue grows, cells descend in neck
- thyroglossal duct - proximal end at the foramen cecum of tongue thyroglossal duct
- thyroid diverticulum - hollow then solid, right and left lobes, central isthmus

Parathyroid function

- 4 glands in the neck on the posterior surface of the thyroid about the size of a grain of rice
- Parathyroid Hormone - Increase calcium ions [Ca2+] in the blood stimulates osteoclasts, increase Ca GIT absorption (opposite effect to calcitonin produced by the parafollicular cells of the thyroid formed from the ultimobranchial body)
- Adult Calcium and Phosphate - Daily turnover in human with dietary intake of 1000 mg/day
- secreted by chief cells
- Principal cells cords of cells

Parathyroid development

Derived from the 3rd – forms the inferior
and 4th pharyngeal pouches – forms the superior
Position swaps round during development
Elongates as a diverticulum and then solidifies in its final location
Epithelium of the 3rd and 4th pouch proliferates during 5th week to form small nodules, which is invaded by vascular mesenchyme to form blood vessels

Pharyngeal clefts and pouches

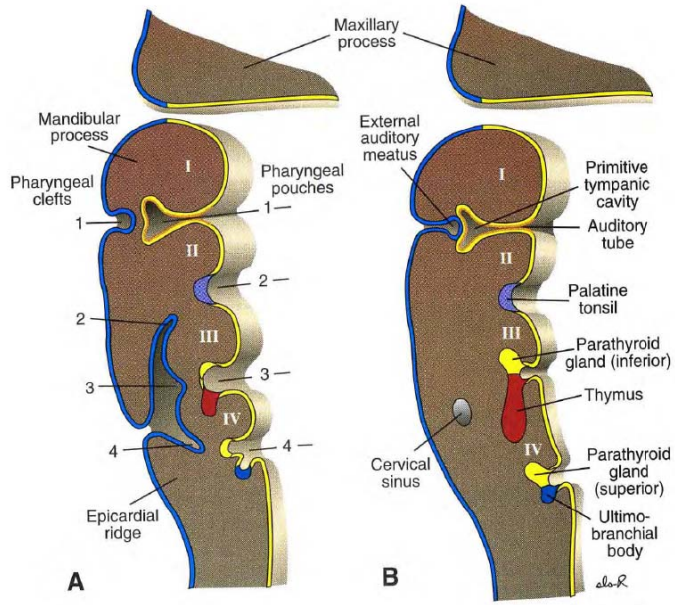

Thymus function

Thymus - bone-marrow lymphocyte precursors become thymocytes, and subsequently mature into T lymphocytes (T cells)

Thymus hormones - thymosins stimulate the development and differentiation of T lymphocytes. Not limited to the thymus.

Thymus Development

Endoderm - third pharyngeal pouch

Week 6 - diverticulum elongates, hollow then solid, ventral cell proliferation

Thymic primordia - surrounded by neural crest mesenchyme, epithelia/mesenchyme interaction

Pharyngeal pouches

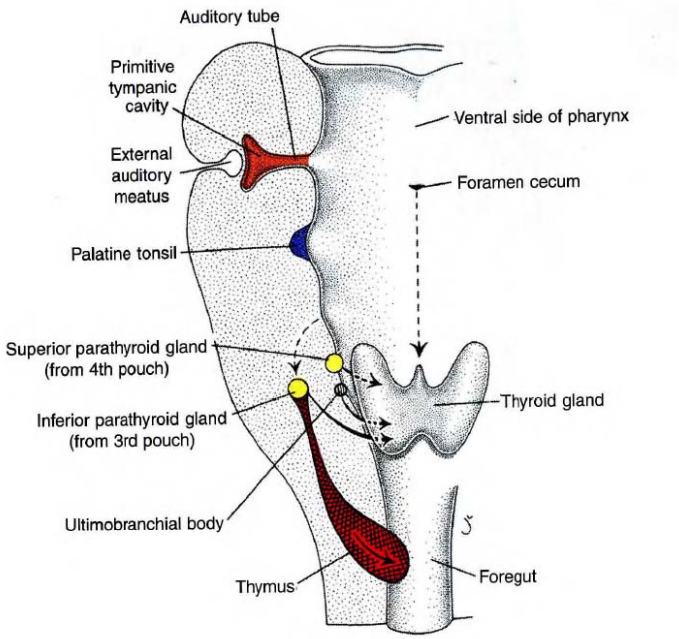

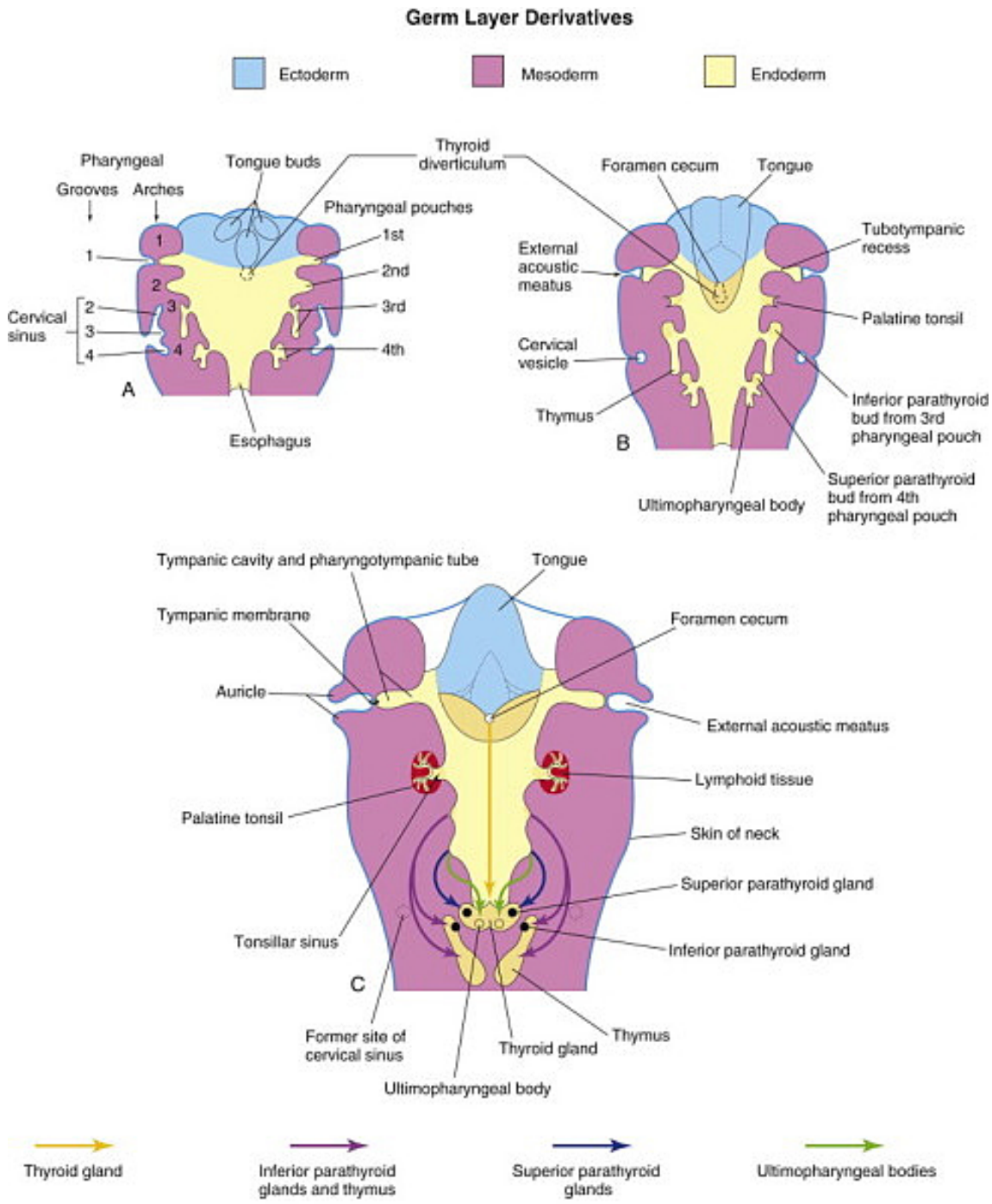
Germ Layer Derivatives
Ectoderm
Mesoderm
Endoderm
Pharyngeal
Grooves
Arches
Tongue buds
Thyroid diverticulum
Pharyngeal pouches
1st
2nd
3rd
4th
Cervical sinus
Esophagus
A
Foramen cecum
Tongue
External acoustic meatus
Tubotympanic recess
Palatine tonsil
Cervical vesicle
Thymus
Inferior parathyroid bud from 3rd pharyngeal pouch
Superior parathyroid bud from 4th pharyngeal pouch
Ultimopharyngeal body
B
Tympanic cavity and pharyngotympanic tube
Tongue
Tympanic membrane
Foramen cecum
Auricle
External acoustic meatus
Lymphoid tissue
Palatine tonsil
Skin of neck
Superior parathyroid gland
Tonsillar sinus
Inferior parathyroid gland
C
Former site of cervical sinus
Thyroid gland
Thymus
Ultimopharyngeal body
Thyroid gland
Inferior parathyroid glands and thymus
Superior parathyroid glands
Ultimopharyngeal bodies

Pancreas development

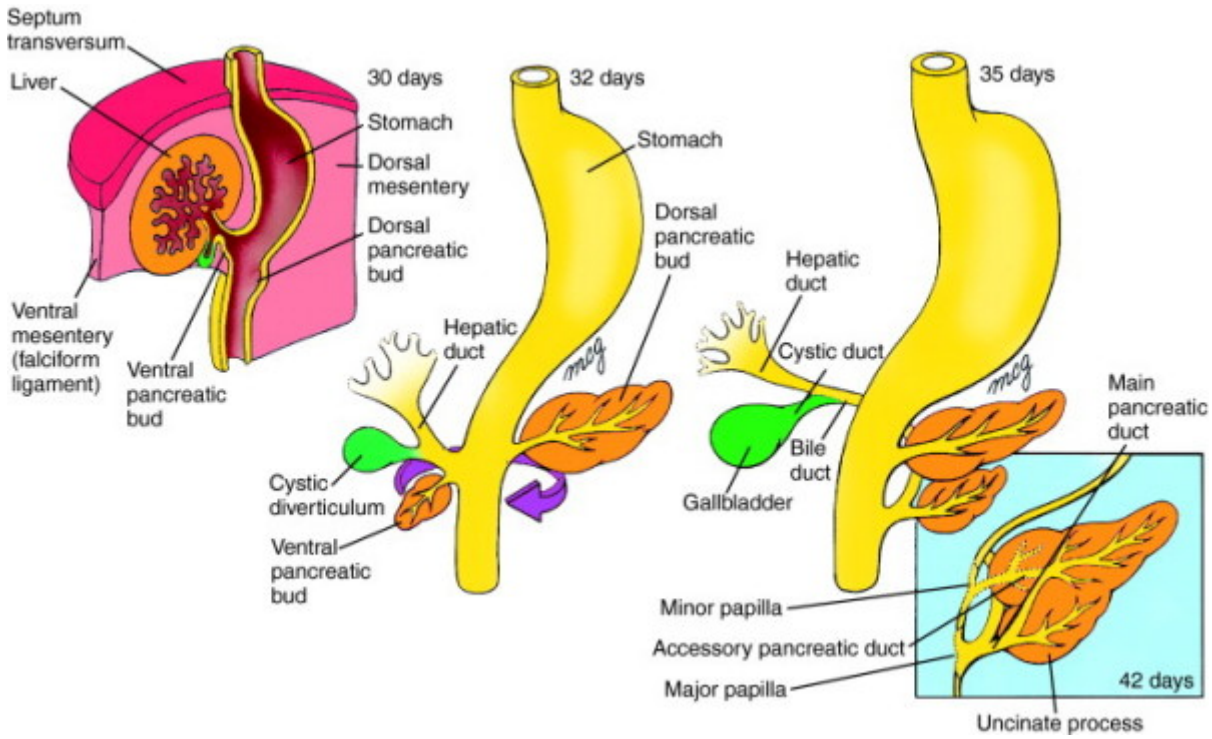

Schoenwolf: Larsen's Human Embryology, 4th ed.

Pancreas

- 99% exocrine function – secretion of pancreatic juice that includes trypsin, chymotrypsin , elastase, carboxypeptidase, pancreatic lipase, nucleases and amylase

Islets of langerhans

- Alpha cells – glucagon (increase glucose)
- Beta cells – insulin (decrease glucose)
- Delta cells – somatostatin (regulates alpha and beta cells)
- Gamma (PP) cells – pancreatic polypeptide (self regulates pancreatic functrion)

Pancreas Timeline

- Week 7 to 20 - pancreatic hormones secretion increases, small amount maternal insulin
- Week 10 - glucagon (alpha) differentiate first, somatostatin (delta), insulin (beta) cells differentiate, insulin secretion begins
- Week 15 - glucagon detectable in fetal plasma

Islet cells (yellow) form during the branching morphogenesis process from endoderm cells.
Note that the pancreas doesn't form branches through folding (e.g. lung). It forms a stratified epithelium which then creates microlumens that coalesce.

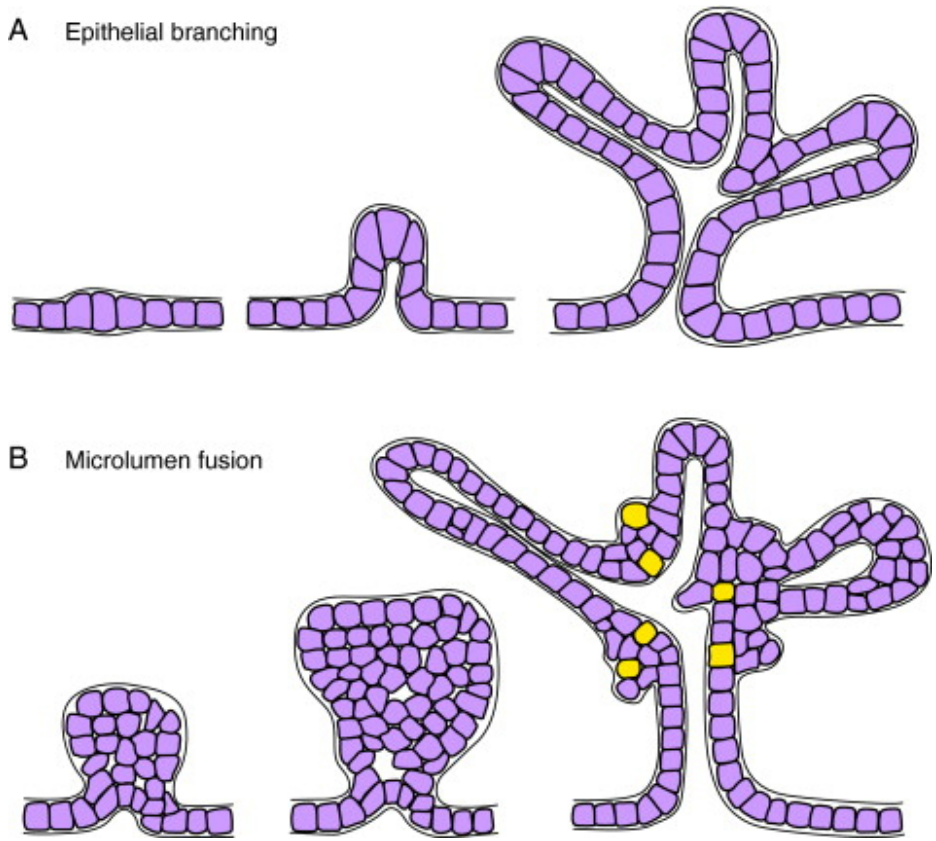

Adrenal glands develop adjacent to the gonads in the urogenital ridge

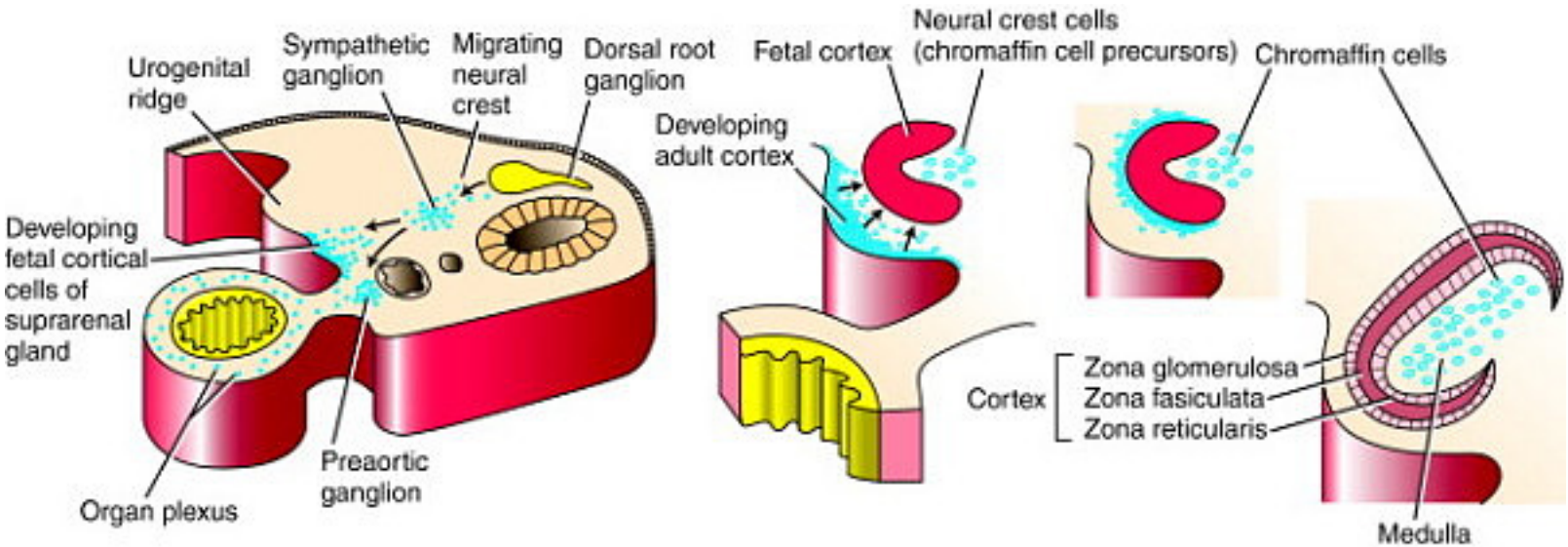

Cortex – mesenchyme, medulla neural crest
6th week cortex begins as aggregation of mesenchyme
Medulla from sympathetic ganglion derived neural crest cells
Later more mesenchymal cells arise from the mesothelium and enclose the cortex
Cortex secretes
Zona glomerulosa – aldosterone (blood pressure)
Zona fasciculata – glucocorticoids
Zona reticularis androgens
Medulla (chromaffin cells) secretes (modified sympathetic ganglion)
20% noradrenaline
80% adrenaline

Suprarenal (adrenal development)

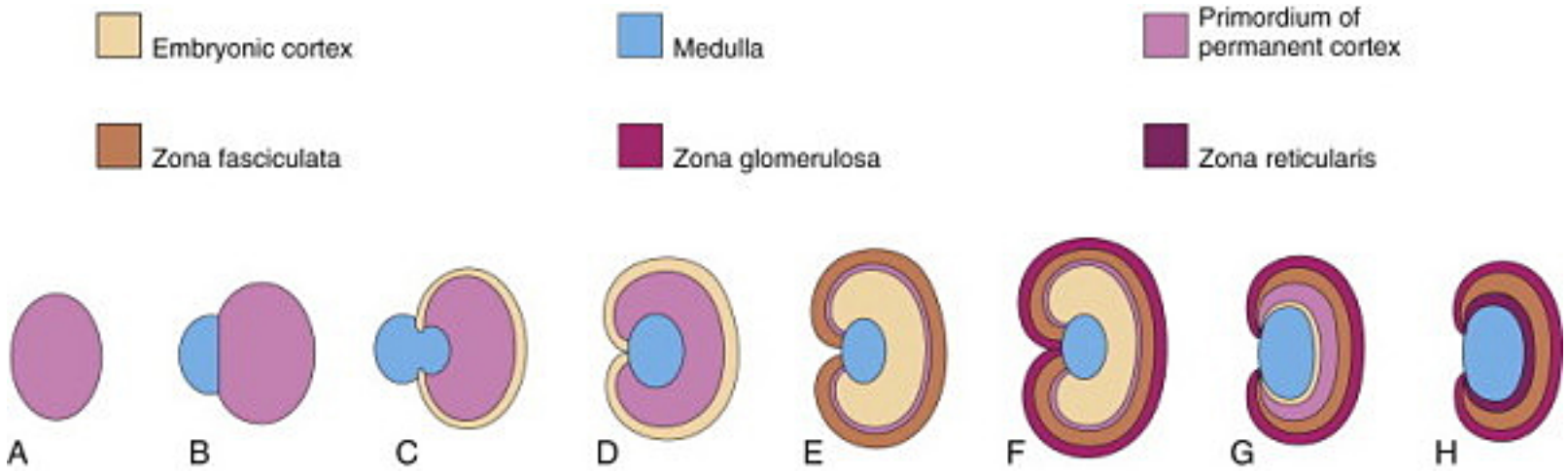

Schematic drawings illustrating development of the suprarenal glands. **A,** At 6 weeks, showing the mesodermal primordium of the fetal cortex. **B,** At 7 weeks, showing the addition of neural crest cells. **C,** At 8 weeks, showing the fetal cortex and early permanent cortex beginning to encapsulate the medulla. **D** and **E,** Later stages of encapsulation of the medulla by the cortex. **F,** Gland of a neonate showing the fetal cortex and two zones of the permanent cortex. **G,** At 1 year, the fetal cortex has almost disappeared. **H,** At 4 years, showing the adult pattern of cortical zones. Note that the fetal cortex has disappeared and that the gland is much smaller than it was at birth (*F*). Zona reticularis present at 3 years old

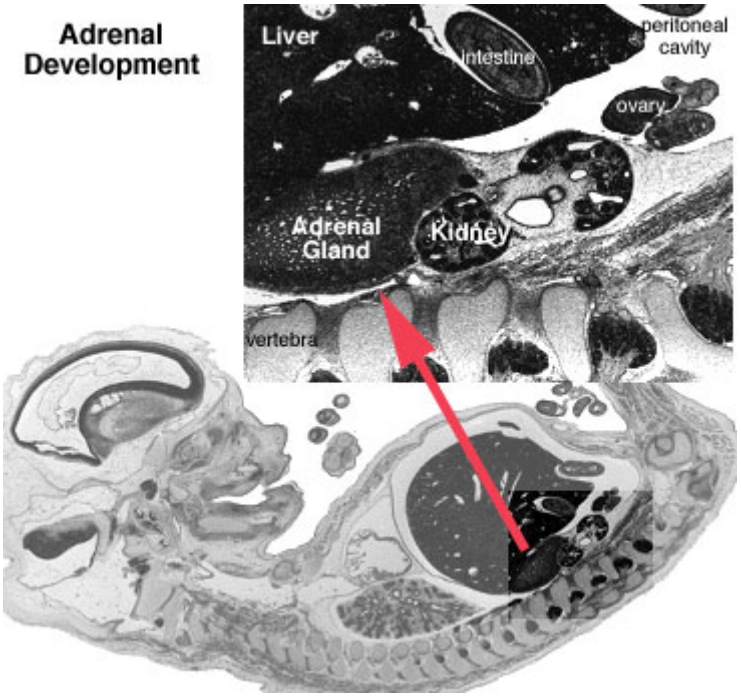

Fetal cortex very large – secretes steroid precursors used by the placenta for the synthesis of oestrogen. The gland shrinks as the embryonic cortex regresses.

Gonads as endocrine organs

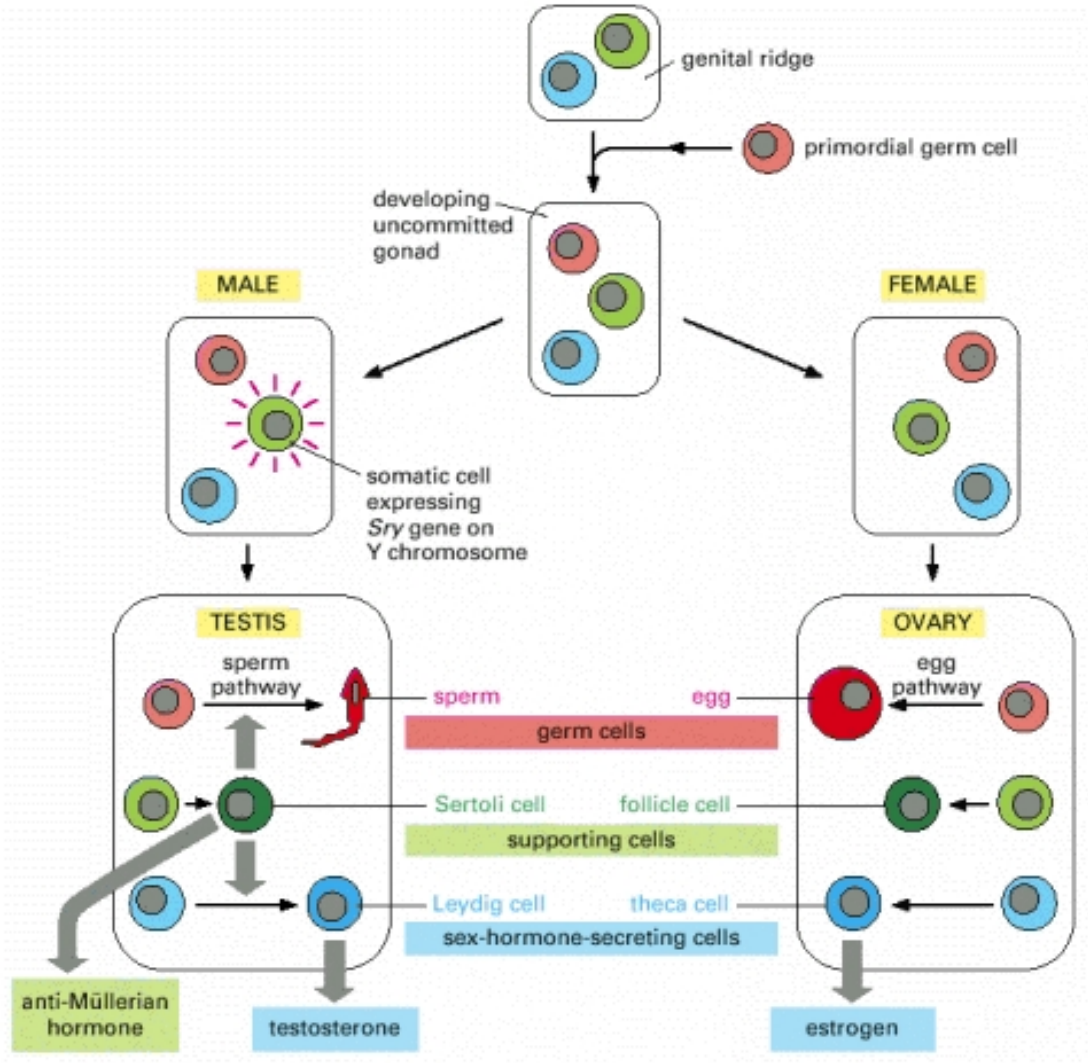

Oogenesis

Menstrual cycle

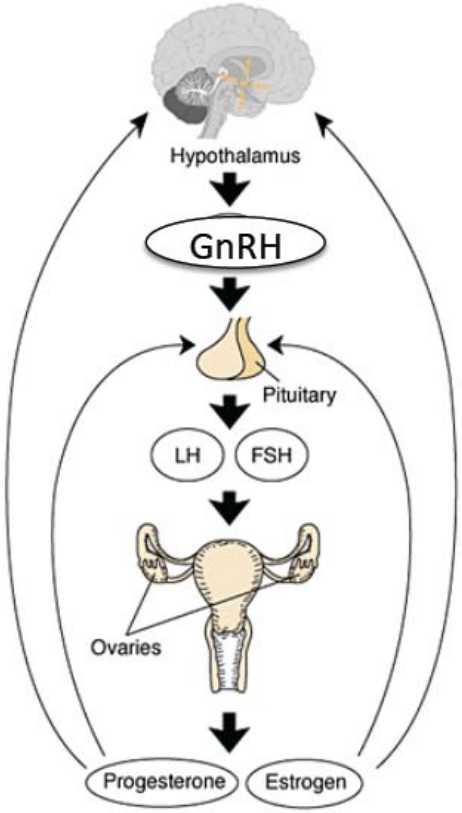

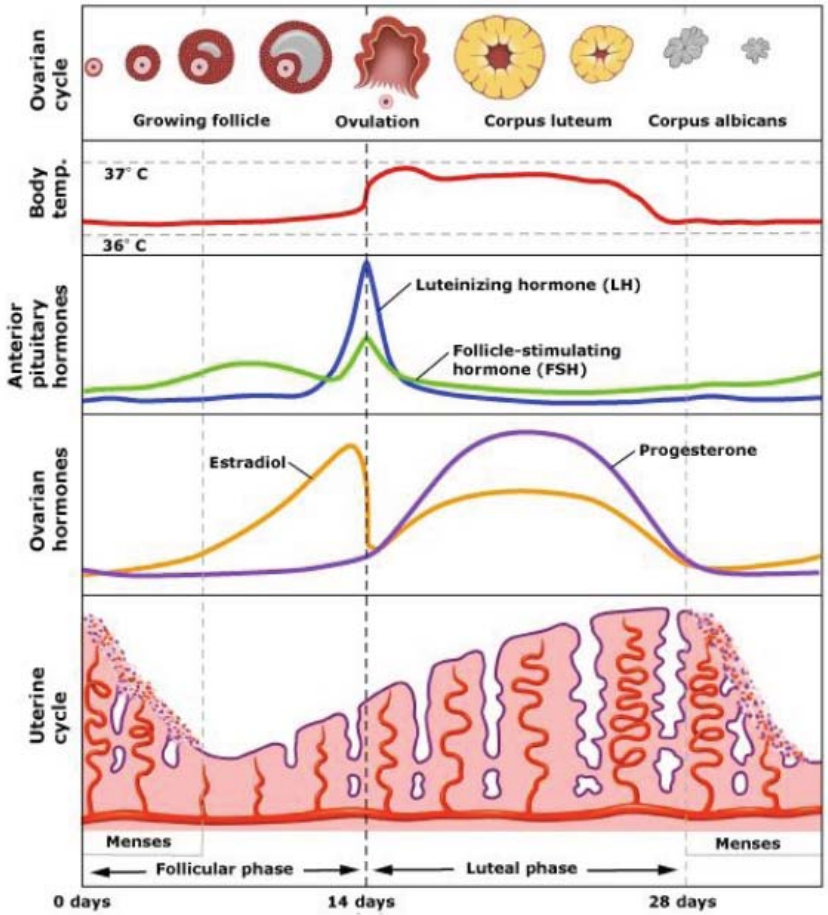

Placenta

- **Human chorionic gonadotropin** (hCG) - like leutenizing hormone, supports corpus luteum in ovary, pregnant state rather than menstrual, maternal urine in some pregnancy testing
- **Human chorionic somatommotropin** (hCS) - or **human placental lactogen** stimulate (maternal) mammary development (possible) – function similar to growth hormone
- **Human chorionic thyrotropin** (hCT) or TSH
- **Human chorionic corticotropin** (hCACTH) or corticotropin-releasing hormone
- **progesterone and oestrogens** - support maternal endometrium
- **Relaxin**

Other

Endocrine Heart
Atrial natriuretic peptide (ANP) - Increase Filtration rate / decrease Na+ reabsorption
Endothelins - ET-1, ET-2, ET-3, Vasoconstriction / Increase NO
Nitric oxide (NO) - Vasodilatation
Endocrine Kidney
Renin - Increase Angiotensin-aldosterone system
Prostaglandins - decrease Na+ reabsorption
Erythropoietin - Increase Erythrocyte (rbc) production
1,25 (OH)2 vitamin D - calcium homeostasis
Prekallikreins - Increase Kinin production
GIT Endocrine
Enteric control of digestive function
Gastrin - Secreted from stomach (G cells), role in control of gastric acid secretion
Cholecystokinin - small intestine hormone, stimulates secretion of pancreatic enzymes and bile
Secretin - small intestine hormone (epithelial cells), stimulates secretion of bicarbonate-rich fluids from pancreas and liver
Adipose Tissue
Leptin - polypeptide hormone produced in adipose and many other tissues with also many different roles
Adiponectin - regulation of energy homeostasis and glucose and lipid metabolism, as well as acting as an anti-inflammatory on the cellular vascular wall
Resistin - (for resistance to insulin, RETN) a 108 amino acid polypeptide and the related resistin-like protein-beta (Resistin-like molecule-beta, RELMbeta) stimulate endogenous glucose production