BGD Lecture - Sexual Differentiation

ExpandEmbryology - 3 Jun 2019 Expand to Translate
Google Translate - select your language from the list shown below (this will open a new external page)
العربية | català | 中文 | 中國傳統的 | français | Deutsche | עִבְרִית | हिंदी | bahasa Indonesia | italiano | 日本語 | 한국어 | မြန်မာ | Pilipino | Polskie | português | ਪੰਜਾਬੀ ਦੇ | Română | русский | Español | Swahili | Svensk | ไทย | Türkçe | | اردو יִידִישׁ | Tiếng Việt These external translations are automated and may not be accurate. (More? About Translations)

Introduction

This lecture covers embryonic sexual differentiation covering gonad, internal and external genital development. Differences in development are dependent on a protein product of the Y chromosome SRY gene. The paired **mesonephric ducts** (Wolffian ducts) and **paramesonephric ducts** (Müllerian ducts) contribute the majority of male and female internal genital tract respectively. I will also introduce some abnormalities of development, that will be covered in the associated practical class. This is one system that continues to develop and change postnatally with puberty and menopause.	♂ Male ♀ Female

2019 Lecture PDF (*Link to be updated - Notice removed when completed*)

ExpandLecture Archive
Links: 2018 | 2018 PDF | 2017 | 2017 PDF | 2016 | 2015 | 2014 | 2014 PDF | 2013 | 2012 | Practical | 2012 Science Lecture

ExpandTextbooks
Hill, M.A. (2019). *UNSW Embryology* (19th ed.) Retrieved June 3, 2019, from https://embryology.med.unsw.edu.au
Genital Links: genital | Lecture - Medicine | Lecture - Science | Lecture Movie | Medicine - Practical | primordial germ cell | meiosis | Female | **X** | ovary | corpus luteum |oocyte | uterus | vagina | reproductive cycles | menstrual cycle | Male | **Y** | SRY | testis | spermatozoa | penis | prostate | endocrine gonad | Genital Movies

| genital abnormalities | Assisted Reproductive Technology | puberty | Category:Genital

ExpandHistoric Embryology - Genital

1901 Urinogenital Tract | 1902 The Uro-Genital System | 1904 Ovary and Testis | 1904 Leydig Cells | 1904 Hymen | 1905 Testis vascular | 1909 Prostate | 1912 Prostate | 1912 Urinogenital Organ Development | 1914 External Genitalia | 1914 Female | 1915 Cowper's and Bartholin's Glands | 1920 Wolffian tubules | 1921 Urogenital Development | 1921 External Genital | 1927 Female Foetus 15 cm | 1932 Postnatal Ovary | 1935 Prepuce | 1935 Wolffian Duct | 1942 Sex Cords | 1943 Testes Descent | 1953 Germ Cells | Historic Embryology Papers | Historic Disclaimer

Moore, K.L., Persaud, T.V.N. & Torchia, M.G. (2015). *The developing human: clinically oriented embryology* (10th ed.). Philadelphia: Saunders. (links only function with UNSW connection)

Chapter 12 Urogenital System

ExpandThe Developing Human: Clinically Oriented Embryology (10th edn)

UNSW Students have online access to the current 10th edn. through the UNSW Library subscription (with student Zpass log-in).

APA Citation: Moore, K.L., Persaud, T.V.N. & Torchia, M.G. (2015). *The developing human: clinically oriented embryology* (10th ed.). Philadelphia: Saunders.

Links: PermaLink | UNSW Embryology Textbooks | Embryology Textbooks | UNSW Library

1. Introduction to the Developing Human
2. First Week of Human Development
3. Second Week of Human Development
4. Third Week of Human Development
5. Fourth to Eighth Weeks of Human Development
6. Fetal Period
7. Placenta and Fetal Membranes
8. Body Cavities and Diaphragm
9. Pharyngeal Apparatus, Face, and Neck
10. Respiratory System
11. Alimentary System
12. Urogenital System
13. Cardiovascular System
14. Skeletal System
15. Muscular System
16. Development of Limbs
17. Nervous System
18. Development of Eyes and Ears
19. Integumentary System
20. Human Birth Defects
21. Common Signaling Pathways Used During Development
22. Appendix : Discussion of Clinically Oriented Problems

Schoenwolf, G.C., Bleyl, S.B., Brauer, P.R., Francis-West, P.H. & Philippa H. (2015). *Larsen's human embryology* (5th ed.). New York; Edinburgh: Churchill Livingstone.(links only function with UNSW connection)

Chapter 15 Development of the Urinary System

Chapter 16 Development of the Reproductive System

ExpandLarsen's Human Embryology (5th edn)
UNSW students have full access to this textbook edition through UNSW Library subscription (with student Zpass log-in). **APA Citation:** Schoenwolf, G.C., Bleyl, S.B., Brauer, P.R., Francis-West, P.H. & Philippa H. (2015). *Larsen's human embryology* (5th ed.). New York; Edinburgh: Churchill Livingstone. **Links:** PermaLink | UNSW Embryology Textbooks | Embryology Textbooks | UNSW Library
1. Gametogenesis, Fertilization, and First Week 2. Second Week: Becoming Bilaminar and Fully Implanting 3. Third Week: Becoming Trilaminar and Establishing Body Axes 4. Fourth Week: Forming the Embryo 5. Principles and Mechanisms of Morphogenesis and Dysmorphogenesis 6. Fetal Development and the Fetus as Patient 7. Development of the Skin and Its Derivatives 8. Development of the Musculoskeletal System 9. Development of the Central Nervous System 10. Development of the Peripheral Nervous System 11. Development of the Respiratory System and Body Cavities 12. Development of the Heart 13. Development of the Vasculature 14. Development of the Gastrointestinal Tract 15. Development of the Urinary System 16. Development of the Reproductive System 17. Development of the Pharyngeal Apparatus and Face 18. Development of the Ears 19. Development of the Eyes 20. Development of the Limbs

Nussey S. and Whitehead S. **Endocrinology: An Integrated Approach** (2001) Oxford: BIOS Scientific Publishers; ISBN-10: 1-85996-252-1.

Chapter 6 The gonad

A Recent Review

Bashamboo A, Eozenou C, Rojo S & McElreavey K. (2017). Anomalies in human sex determination provide unique insights into the complex genetic

interactions of early gonad development. *Clin. Genet.* , *91*, 143-156. PMID: 27893151 DOI.

> Human sex determination (SD) involves complex mutually antagonistic genetic interactions of testis- and ovary-determining pathways. For many years, both male and female SD were considered to be regulated by a linear cascade of pro-male and pro-female genes, respectively; however, it has become clear that male and female development is achieved through the repression of the alternative state. A gene determining the formation of a testis may function by repressing the female state and vice versa. Uniquely in development, SD is achieved by suppression of the alternate fate and maintained in adulthood by a mutually antagonistic double-repressive pathway. Here, we review genetic data generated through large-scale sequencing approaches that are changing our view of how this system works, including the recently described recurrent NR5A1 p.R92W mutation associated with testis development in 46,XX children. We also review some of the unique challenges in the field to establish that mutations, such as this are pathogenic. The impending surge of new genetic data on human SD from sequencing projects will create opportunities for the development of mechanistic models that will clarify how the system operates and importantly provide data to understand how selection and developmental processes interact to direct the evolution of SD across species.

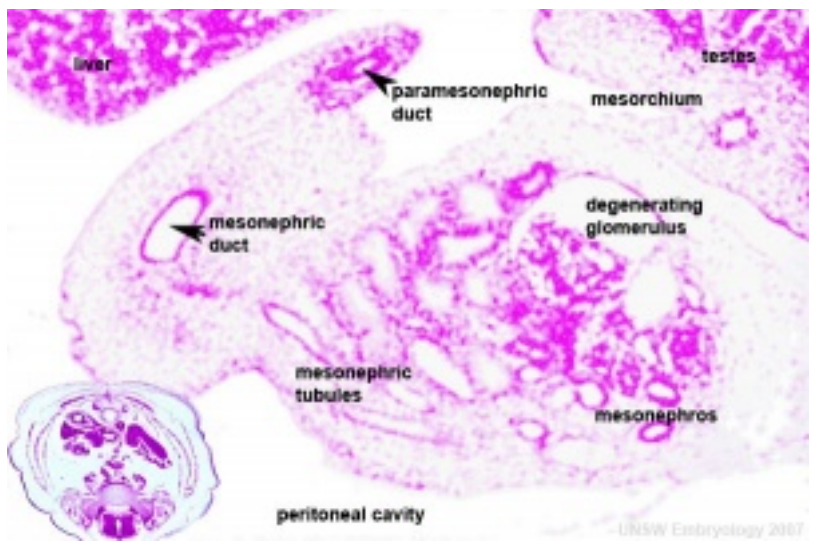

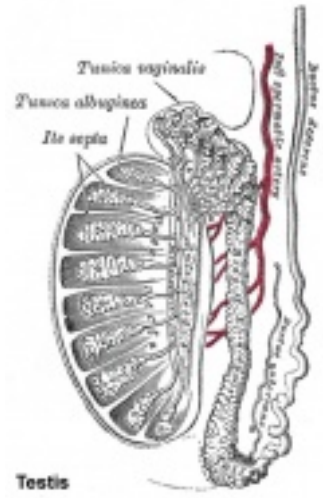

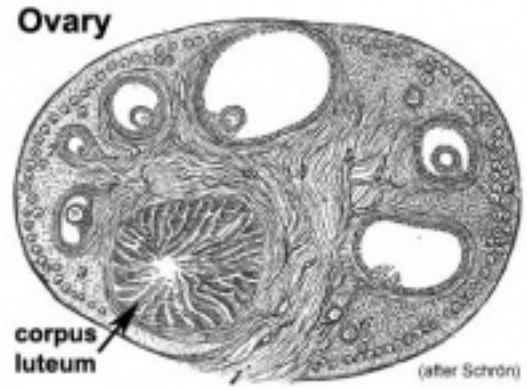

Objectives

- Understand the development of the gonads in males and females.
- Understand the chromosomal basis of sex determination.
- Understand the differences in male/female internal duct develpoment.
- Understand the origins of the external genitalia.
- Understand the developmental abnormalities in male and female development.

Stages of Sexual Differentiation

1. Development of the **indifferent gonad** - (genital ridge) early embryo
2. Differentiation of gonad - (**testis or ovary**) late embryo, defining event in sexual differentiation
3. Differentiation of **internal genital organs** and ducts - late embryo to fetal
4. Differentiation of **external genitalia** - fetal
5. Development of **secondary sexual characteristics** - puberty

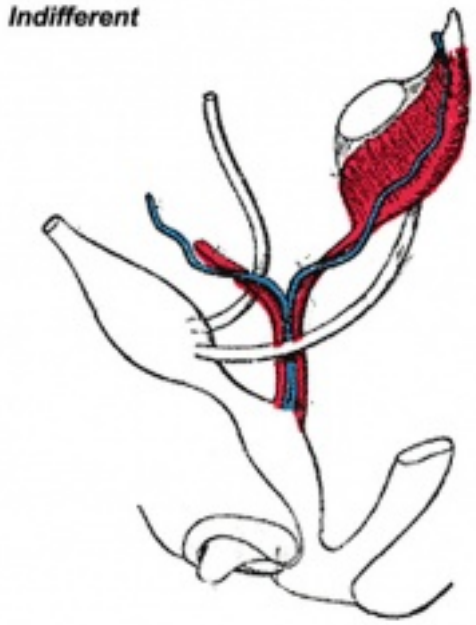

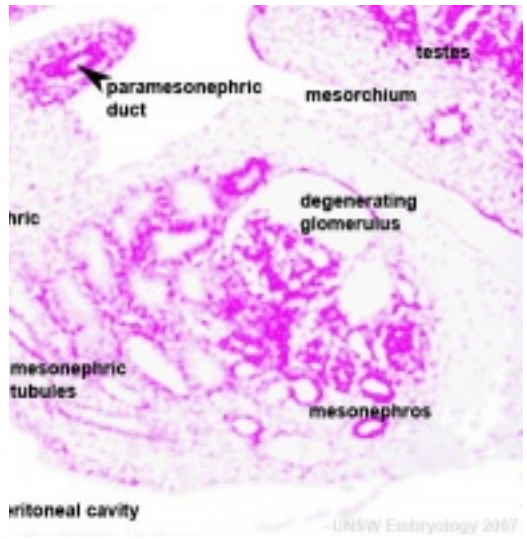

ephros

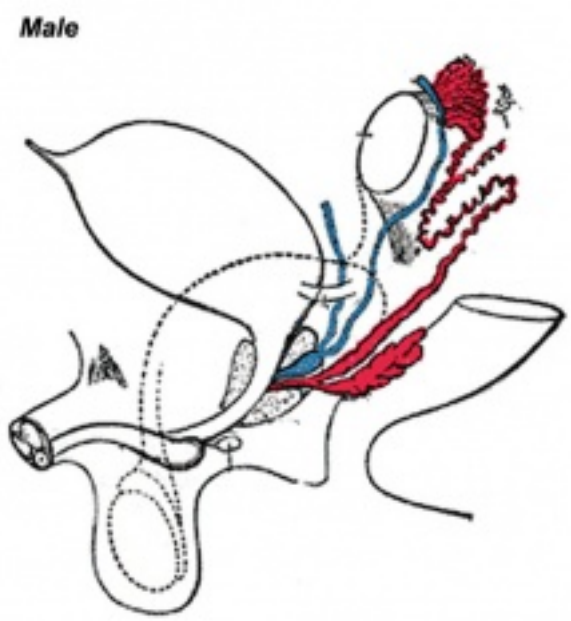

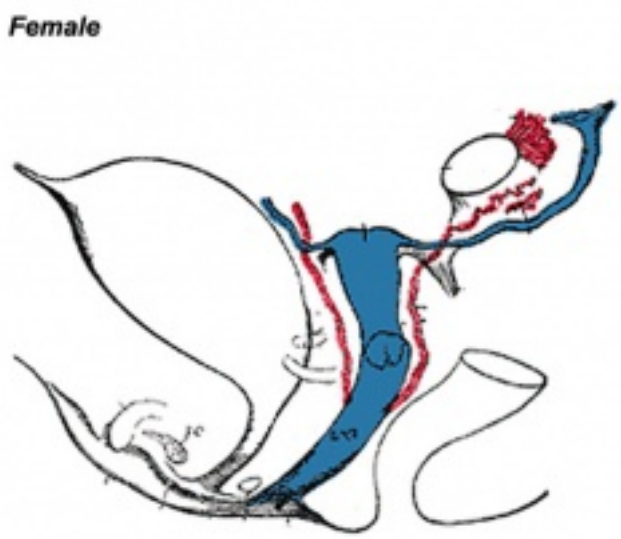

Human Timeline

• **Week 3-4** - primordial germ cells migrate during gastrulation • **Week 4** - (24 days) intermediate mesoderm, pronephros primordium • **Week 5** - (28 days) mesonephros and mesonephric duct • **Week 6** - (35 days) ureteric bud, metanephros, genital	

ridge
- **Week 7** - (42 days) cloacal divison, gonadal primordium - indifferent to first appearance of testis cords
- **Week 8** - (49 days) paramesonephric duct, clear gonadal differentiation
- **Week 9** - (56 days) paramesonephric duct fusion (female)
- **Week 15** - (100 days) primary follicles (ovary)

1. Development of the indifferent gonad

- **intermediate mesoderm** - (between somites and lateral plate mesoderm) kidneys and genital ridge develop.
- **kidney multiple stages** - occur in a rostrocaudal sequence
  - **pronephros** > **mesonephros** > **metanephros** (true adult kidney)
- **pronephros** (week 4) earliest structure to form featuring a pronephric duct with associated nephrogenic mesenchyme.
  - pronephros degenerates - leaving only the duct system running down to the cloaca (**mesonephric duct** = Wolffian duct).
- **mesonephros** - next stage a series of mesonephric tubules in the mesenchyme that are induced by the mesonephric duct.
  - mesonephros degenerates - in mammals (In fish and amphibians it is the functioning adult kidney).
  - In mammals it serves mainly as the site for gonadal development.

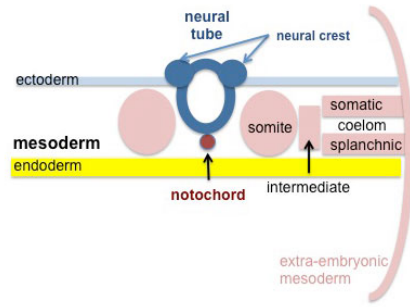

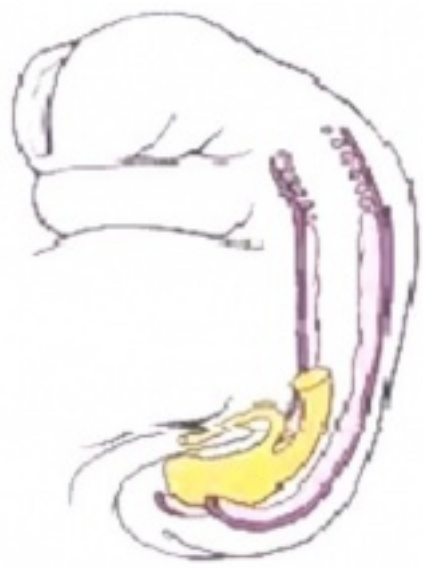

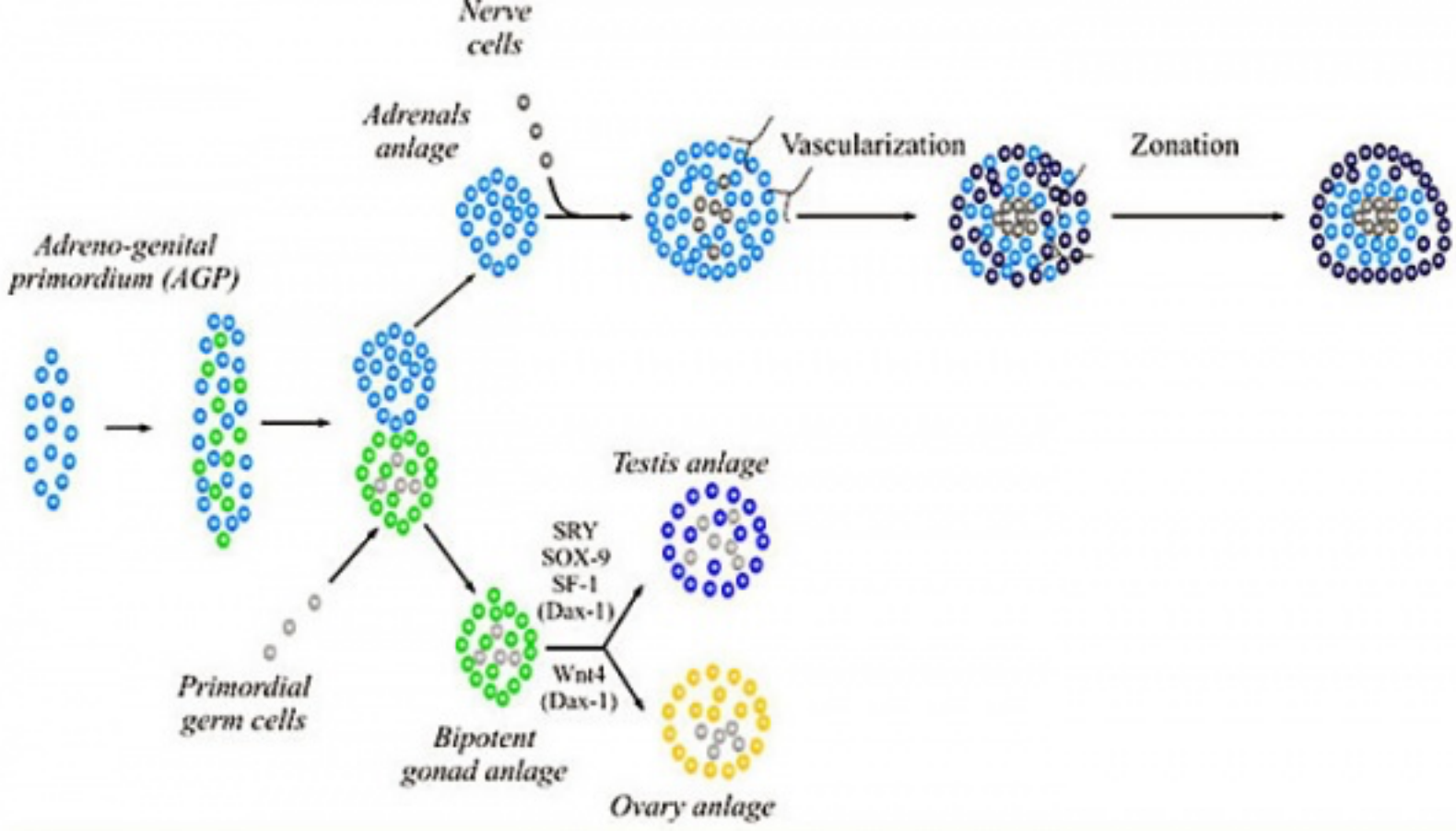

Gonad and adrenal early development (not required to know molecular information)

2. Differentiation of gonad into testis or ovary

Chromosomal Sex Determination

Males	
Y Chromosome • 59 million base pairs, hypervariable in length, mostly non-functional repeats • Current known protein-coding genes = 48 including *SRY* • *SRY* encodes a 204 amino acid protein (TDF) that is a member of the HMG (High mobility group) box class of DNA-binding proteins. Transcription factors bind to specific sites of DNA and regulates the transcription (expression) of other genes.	X Chromosc • 155 mi contair haploic encode and sp • Genes DAX-1 initiatic ovary c

	
	X Inactivatic • one X c randon throug embryo • mosaic patern chrom tissues

Links: MBoC - Figure 20-18. Influence of Sry on gonad development | image (image provides a good overview of the anatomy of sex determination, I will refer to this in the lecture and practical class)

Supporting Cells

- So called because they "support" the germ cells

Males	Fema
sertoli cells • SRY is expressed in the primordia of the supporting cells, transforming them into Sertoli cells that surround the germ cells and form testis cords ◦ SRY is not expressed in the other cell types of the gonad	Granulosa cells • Follicle cells surro the developing oo

• Sertoli cells instruct the germ cells and the steroid secreting cells to take the male path of development	
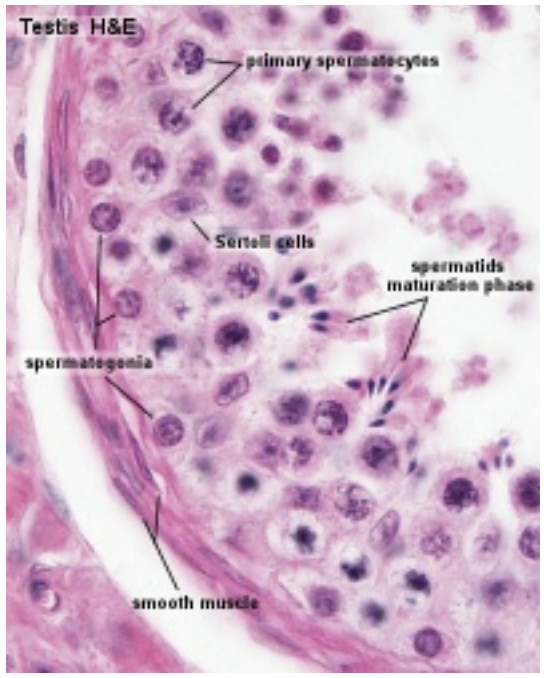	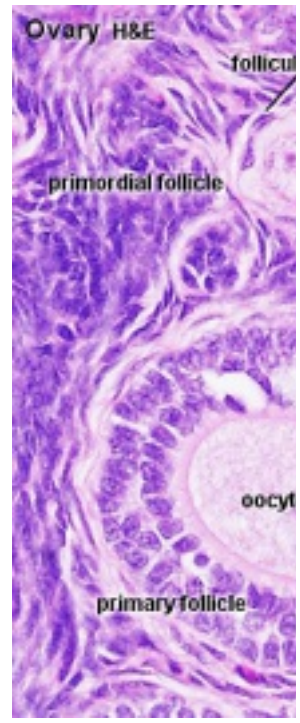

• embryonic cells - secrete anti-Mullerian hormone (AMH)
• adult cells - line the inside of the seminiferous tubules and support spermatogenesis.
	• adult cells - in res
	follicle cells prolif
	  ◦ After ovulati
	  become lute
	  corpus luteu
	  progesteron

Steroid secreting cell lineage

Males	Females
Leydig cells • (interstitial cells) that sit outside the seminiferous tubules • Secrete **testosterone** in response to luteinizing hormone from the pituitary	Theca cells • that sit outside the follicle • Secrete **androstenedione** converted by the follicle c

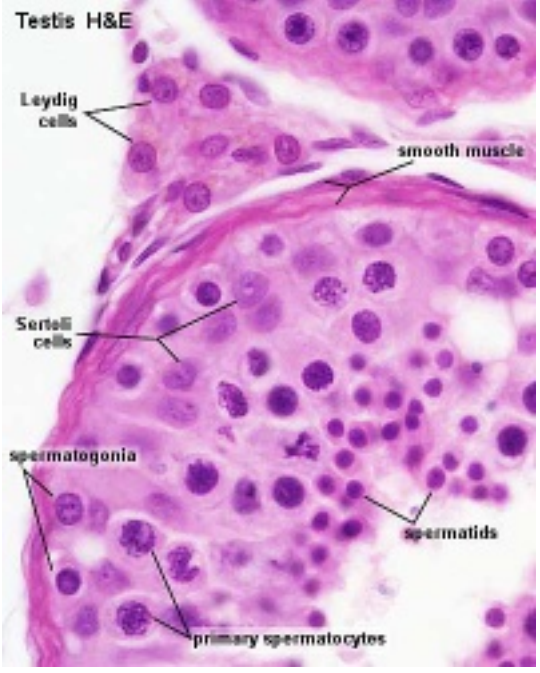

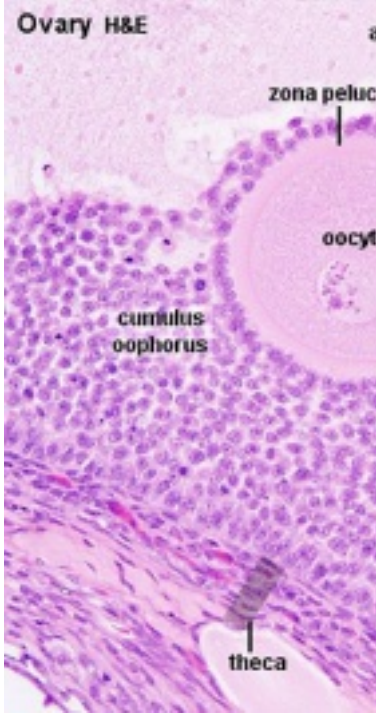

Primordial Germ Cells

- Primordial germ cells (PGCs) are thought to be the first population of cells to migrate through the primitive streak in early gastrulation (week 3)
- cells then lie at the hindgut yolk sac junctional region
- later migrate into the genital ridge (germinal ridge) in early embryonic development.

Primordial germ cell region (Stage 9)

Mouse Primordial Germ Cell Migration		
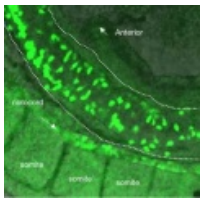	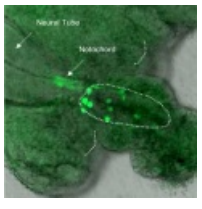	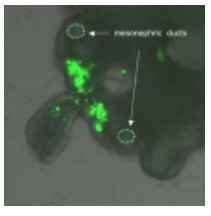
Germ Cell E9.0	**Germ Cell E9.5**	**Germ Cell E10.5**
Page | Play	Page | Play	Page | Play

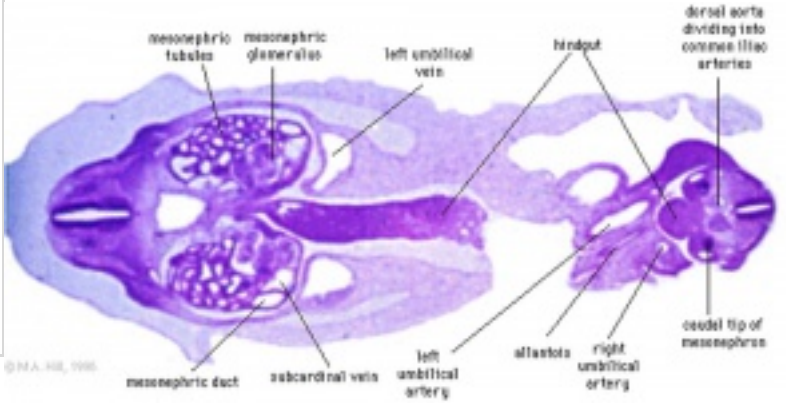

Genital Ridge (Stage 13)

- **Not the primordial germ cells**

which respond to SRY presence or absence, but the supporting cells within the developing gonad.

- Germ cells occasionally migrate by mistake into the developing adrenal gland and in the absence of sertoli cells telling them what to do, abnormally begin to develop as oocytes, even in males

Links: Germ cell migration pathway

Gametogenesis

- forming PGCs as a small population of migratory cells
- enter the gonad where they undergo several rounds of mitotic cell division
- female - the germ cells enter meiosis and become arrested at the dictyate (diplotene) stage of meiotic prophase 1. All oocytes are at this stage at birth
- male - the germ cells are enclosed by the developing Sertoli cells and are induced to arrest differentiation and cell division as T1 prospermatogonia until after birth.

Links: Image - Spermatogenesis | Image -Oogenesis

3. Differentiation of internal genital organs and ducts

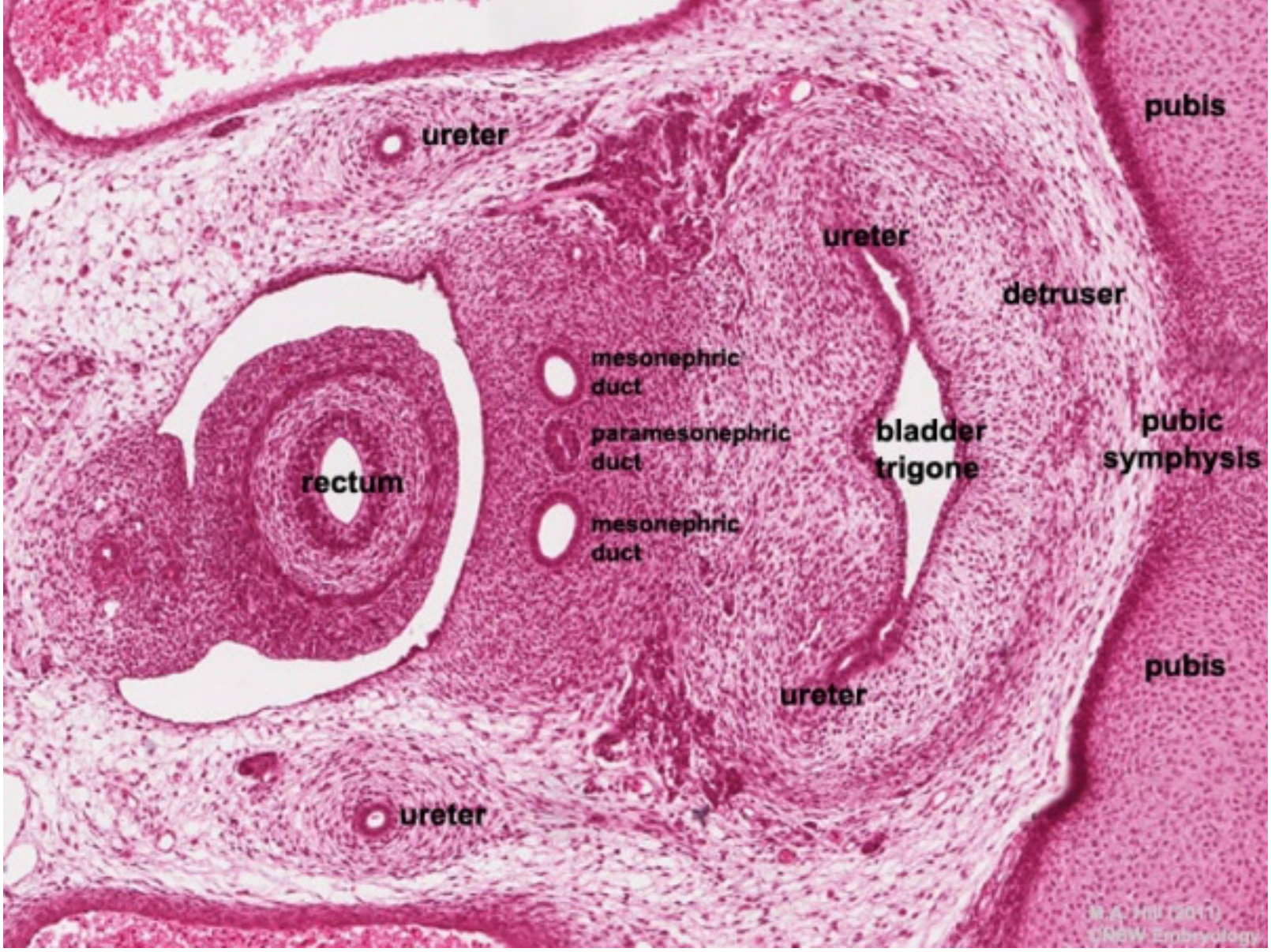

Human embryo (Carnegie stage 22, week 8) pelvic level cross-section.

Male

This looped animation shows the development of the male gonad showing medullary sex cords.

- The paramesonephric duct (red, left) degenerates under the influence of anti-Mullerian hormone (AMH) secreted by sertoli cells.
- The mesonephric duct (purple) is maintained and differentiates under the influence of Testosterone secreted by Leydig cells. Within the testes these mesonephric tubules grow towards the testis cords and will form the rete testis. The mesonephric duct extending out of the gonad forms the ductus deferens.
- The testis cords (orange) containing the Sertoli cells and the germ cells (which are arrested as T1 prospermatogonia until after birth) later differentiate into seminiferous tubules which become hollow and actively produce spermatazoa during puberty.

The tunica albuginea (white) covers the testis and bands extend

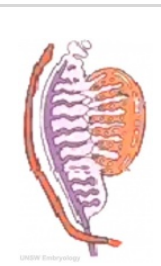

Testis

Page |

inward to form connective tissue septa.	Play

Anti-Mullerian Hormone

Anti-Mullerian hormone (AMH) or Mullerian Inhibiting Substance (MIS) hormone with at least two gonadal related functions:

- In males, it is produced by embryonic Sertoli cells and causes the loss of the paramesonephric (Mullerian) duct system that forms the internal female genital tract.
- In females, it is produced after puberty by follicle cells and suppresses the development of other primary follicles, thus restricting the number of follicles stimulated by FSH.

Female

This looped animation shows the development of the female gonad showing cortical sex cords. • The mesonephric duct (purple) degenerates, small remnants may remain as epoophoron and paroophoron (in the mesentry of the ovary) and Gartner's cycts (near vagina). • The paramesonephric duct (red, left) grows forming the oviducts (fallopian tubes) and the end opens into the peritoneal cavity and terminates in fimbria (finger-like extensions). Away from the ovary, the two paramesonephric ducts fuse in the midline to form the uterus. • After entry of the germ cell into meiosis they are called oocytes and they are surrounded by the derivatives of the supporting cell lineage - the follicle cells or granulosa cells. • About 95% of the germ cells that entered meiosis in the female will be lost by a process called follicular atresia (see graph. Only about 400,000 remain at the time of puberty.	

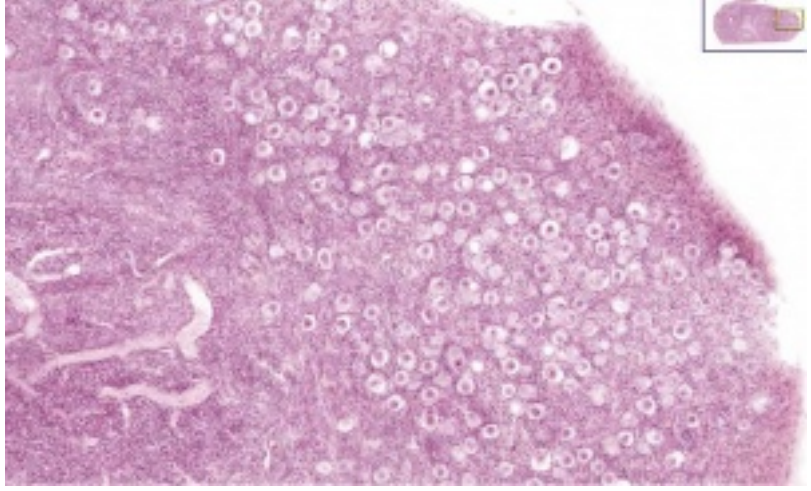

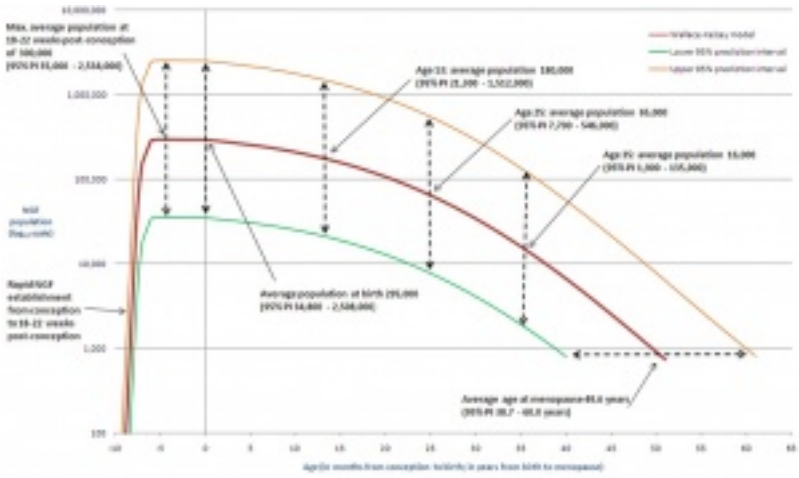

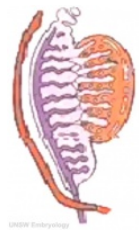

Ovary

Page | Play

Uterus Development

- **Week 7** – duct preservation or regression begins

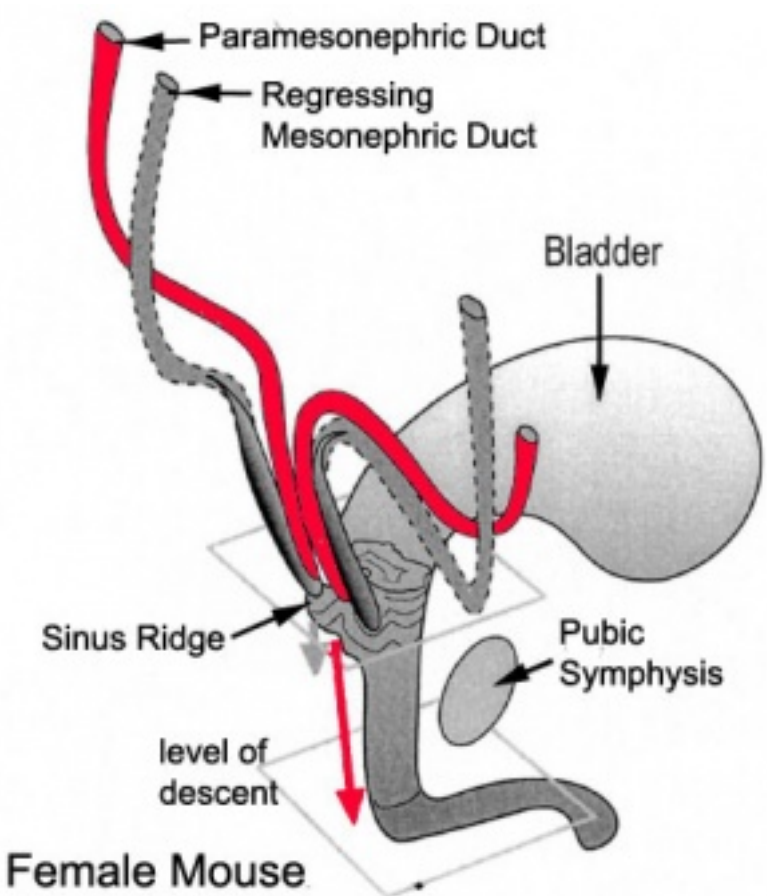

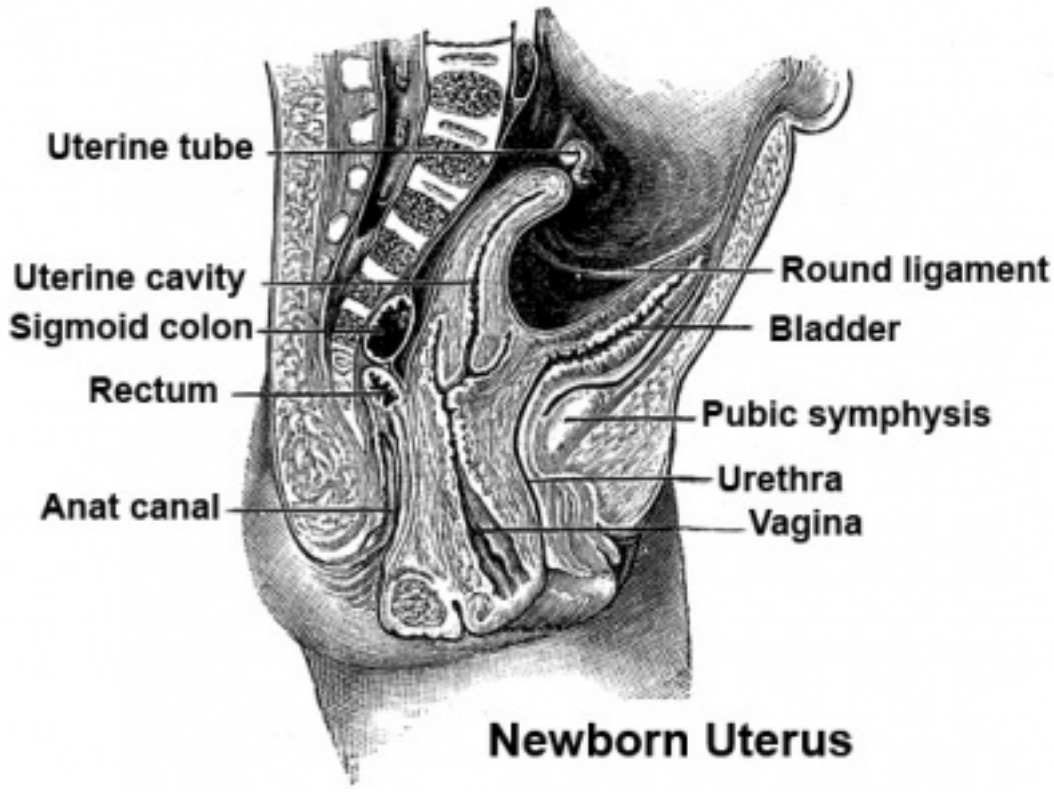

Paramesonephric duct development

Vagina Development

- The embryonic origin of the vagina has been a historically hotly debated issue with several different contributions and origins described.
- Current molecular studies show the whole vagina is derived from the intermediate mesoderm-derived Paramesonephric (Müllerian) duct[1] (see also earlier review [2])
    - bone morphogenic protein 4 (BMP4) reshapes the duct into the vaginal primordium.
- exhibits different features from the uterus
    - stratified squamous epithelium
    - insensitivity to anti-Müllerian hormone

Links: Vagina Development

4. Differentiation of External Genitalia

• external genitalia are initially identical and undergo male and female differentiation under the influence or absence of steroidal sex hormones. • Indifferent stage – cloaca divided by proliferating mesenchyme forming the urorectal septum which	

separates the ventral urogenital sinus from the dorsal rectum.
- Difference stage – locally in this region the presence or absence of **dihydrotestosterone** (DHT), generated from testosterone, determines male/female development.

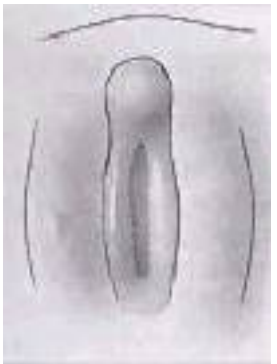

[Endocrinology - Diagram of the development of the external genitalia](#) | [image](#)

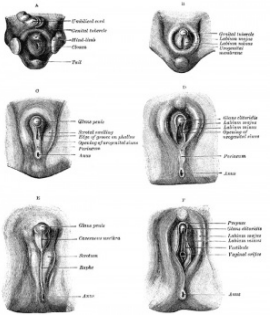

Genital external development

Dihydrotestosterone (DHT)

Male presence of DHT

- locally in this region leads to **genital tubercle** growth, form change.
- **genital folds** (urethral) initial maintenance and then fusion, forming perineal and penile raphe.
- **labioscrotal swellings** (lateral to urethreal folds) become the scrotum.

Female absence of DHT

- genital tubercle remains small, bends caudally to form the clitoris.
- genital folds (urethral) persist, do not fuse, and form labia minora.
- open urogenital sinus forms a cleft into which urethra and vagina open.
- labioscrotal swellings become the labia majora.

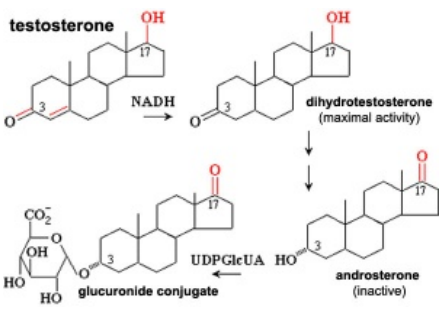

Testosterone metabolism

Female

This looped animation shows the development of external female genitalia from the indifferent external structure, covering the approximate period of week 9 to 12.

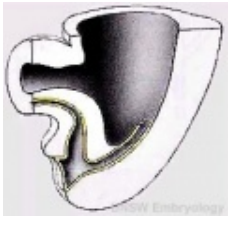 **Urogenital Septum** Page | Play	 **Female External** Page | Play	Note the original cloacal membrane becomes separated into the urogenital membrane and anal membrane. The urogenital folds beneath the genital tubercle remain separate (unfused), forming the inner labia minora and second outer skin folds form the larger labia majora either side of the developing vestibule of the vagina. Note at the top of the animation, the changing relative size of the genital tubercle as it forms the glans of the clitoris.	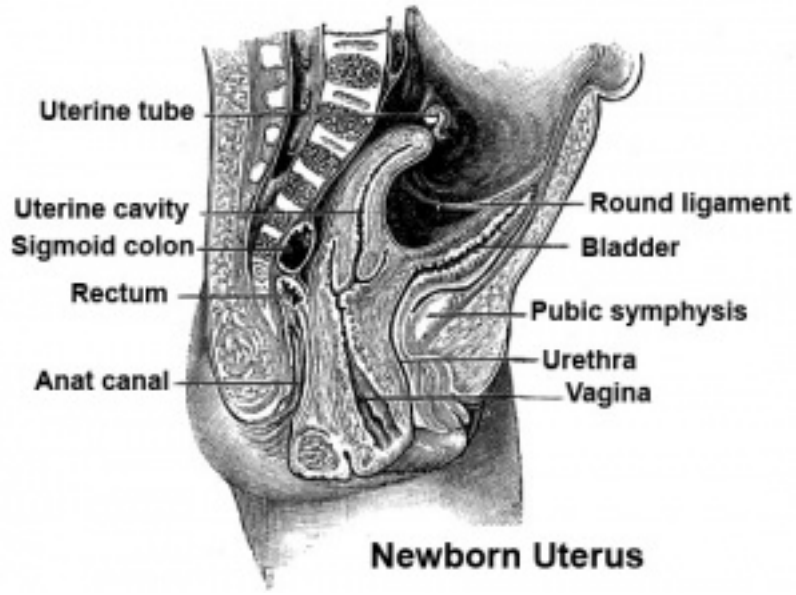 Newborn uterus

Male Genitalia Development

Endocrinology - Box 6.6 The roles of testosterone (T) and 5α-dihydrotestosterone (DHT)

This looped animation shows the development of external male genitalia from the indifferent external structure, covering the approximate period of week 9 to 12.

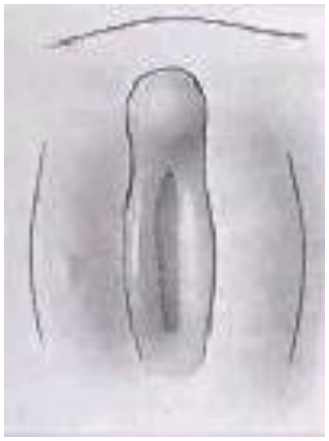

Male External

Page | Play

Note the original cloacal membrane becomes separated into the urogenital membrane and anal membrane (identical to female). The urogenital folds beneath the genital tubercle begin to fuse in the midline. The skin folds either side for the scrotum, which too has a midline fusion, the raphe. The scrotal sac is initially empty and is an attachment site for the gubernaculum, descent of the testes begins generally during week 26 and may take several days.

Gonad Descent

- Both kidney and gonads develop retroperitoneally, with the gonads moving into the abdomen or eventually into the scrotal sacs.
- During fetal development the gubernaculum and fetal growth in both male and female, changes the gonads' relative positions finally reaching their adult locations.

Both female and male gonads undergo anatomical descent.

- **Ovaries** – undergo caudal and lateral shifts to be suspended in the broad ligament of the uterus, gubernaculum does not shorten, it attaches to paramesonephric ducts, causing medial movement into the pelvis.

- **Testes** – two anatomical phases in descent, transabdominal and transinguinal, under the influence of the shortening gubernaculum.

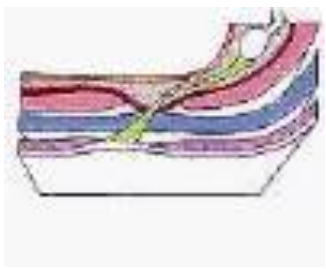

Testis Descent

Page | Play

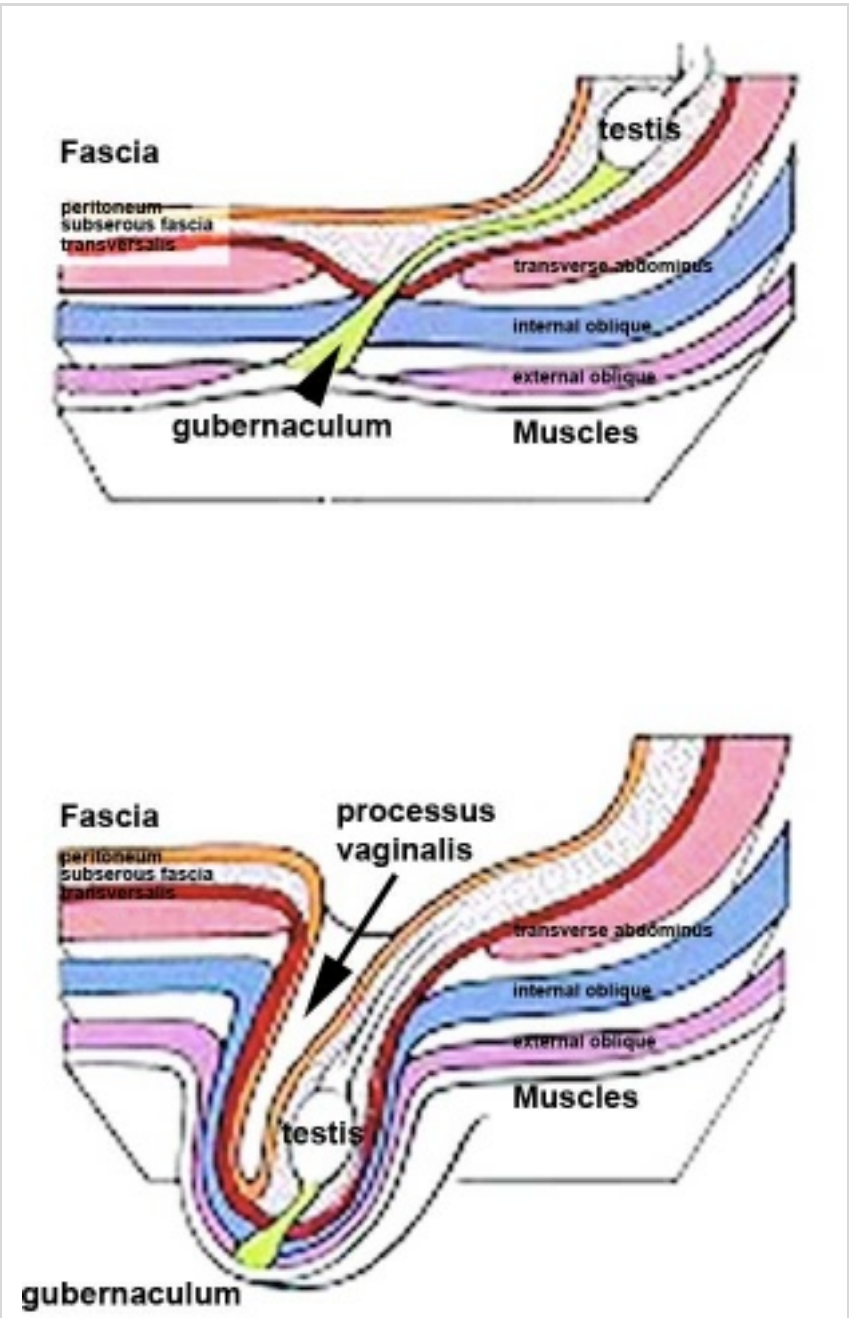

The testis (white) lies in the subserous fascia (spotted) a cavity processus vaginalis evaginates into the scrotum, and the gubernaculum (green) attached to the testis shortens drawing it into the scrotal sac. As it descends it passes through the inguinal canal which extends from the deep ring (transversalis fascia) to the superficial ring (external oblique muscle). Descent of the testes into the scrotal sac begins generally during week 26 and may take several days. The animation shows the path of a single testis.

Data from a recent study of male human fetal (between 10 and 35 weeks) gonad position.

- 10 to 23 weeks - (9.45%) had migrated from the abdomen and were situated in the inguinal canal
- 24 to 26 weeks - (57.9%) had migrated from the abdomen
- 27 to 29 weeks - (16.7%) had not descended to the scrotum

Incomplete or failed descent can occur unilaterally or bilaterally, is more common in premature births, and can be completed postnatally.

5. Postnatal - Puberty

Puberty can occur over a broad range of time and differently for each sex:

- girls (age 7 to 13)
- boys (age 9 to 15)

The physical characteristics that can be generally measured are: genital stage, pubic hair, axillary hair, menarche, breast, voice change and facial hair.

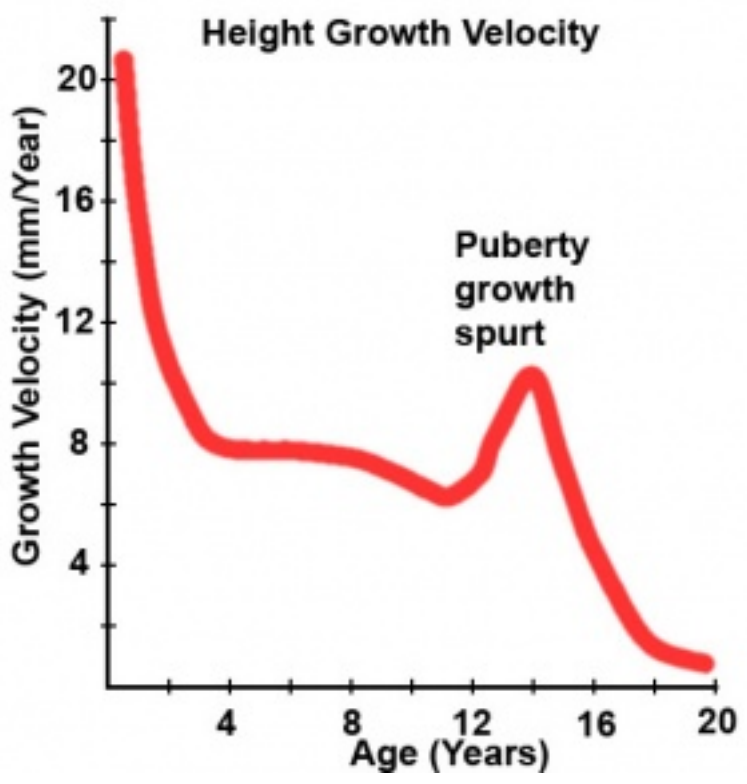

Puberty growth

Male

- testosterone - adult testes produce about 6-10 mg /day in males (~0.5 mg / day in females) carried in circulation by a specific carrier globulin.
- masculinizing androgen - also at puberty, spermatogenesis in males
- development of secondary sexual characteristics - body and facial hair growth (male pattern baldness)
- anabolic effect - metabolism towards conservation of amino acids, promoting protein synthesis, muscle development
- neural - libido in both sexes, male pattern behaviour

- {{Sertoli cell))s (Sustentacular) - produce anti-mullerian hormone (AMH) to puberty.
    - **AMH** - anti-Müllerian hormone (Müllerian inhibiting factor (MIF), Müllerian-inhibiting hormone (MIH), and Müllerian-inhibiting substance (MIS)).

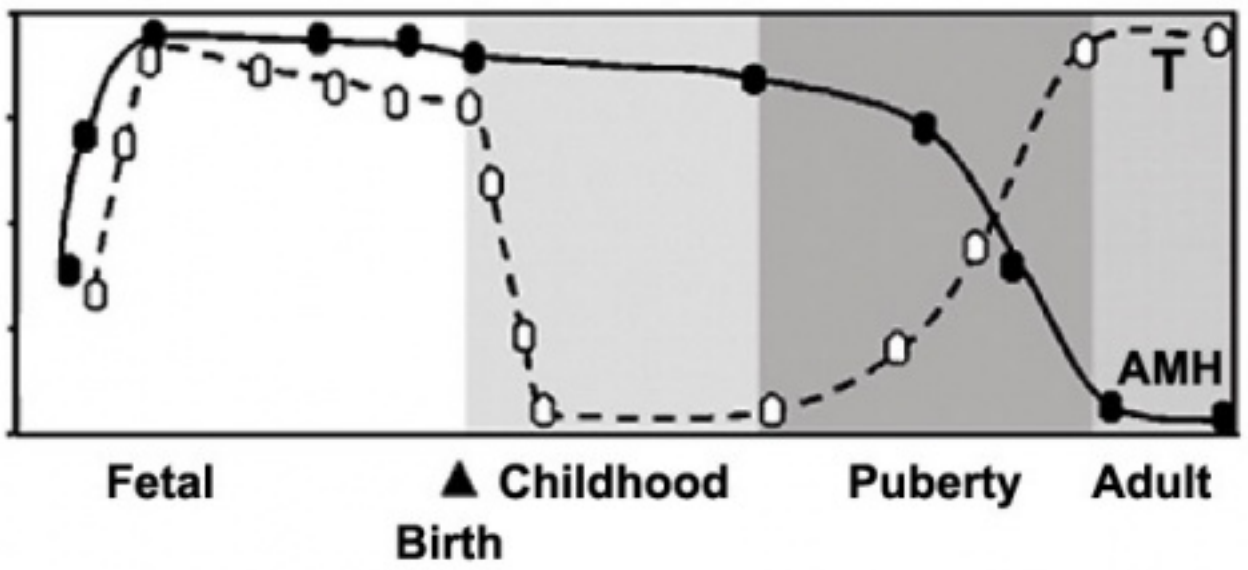

Female

In females, menarche (the first menstruation or a period) usually occurs after the other secondary sex characteristics, and will continue until menopause (permanent cessation of reproductive fertility).

The diagram shows the hormonal regulation pathway from the brain to the ovary and subsequent impact on uterine changes during the menstral cycle.

- **GnRH** = Gonadotropin-releasing hormone (GnRH). This peptide hormone is a decapeptide (10 amino acids) with a short half life (<15 minutes).
- **LH** = Luteinizing Hormone
- **FSH** = Follicle Stimulating Hormone

A similar endocrine axis is also found for regulation of the male gonad.

- Hypothalamus - Pituitary - Gonad (female)

- Hypothalamus - Pituitary - Gonad (male)

Puberty Abnormalities

- **Precocious Puberty** - Premature development of the signs of puberty which can occur in both girls (before age 7 or 8) and in boys (before age 9).
- **Delayed Puberty** - Determined in boys by a lack of increase in testicular volume by the age of 14 years. In girls, no breast development by the age of 13.5 years and a lack of menstruation by the age of 16 years. There can also be a "pubertal arrest" where there is no progress in puberty over 2 year period.

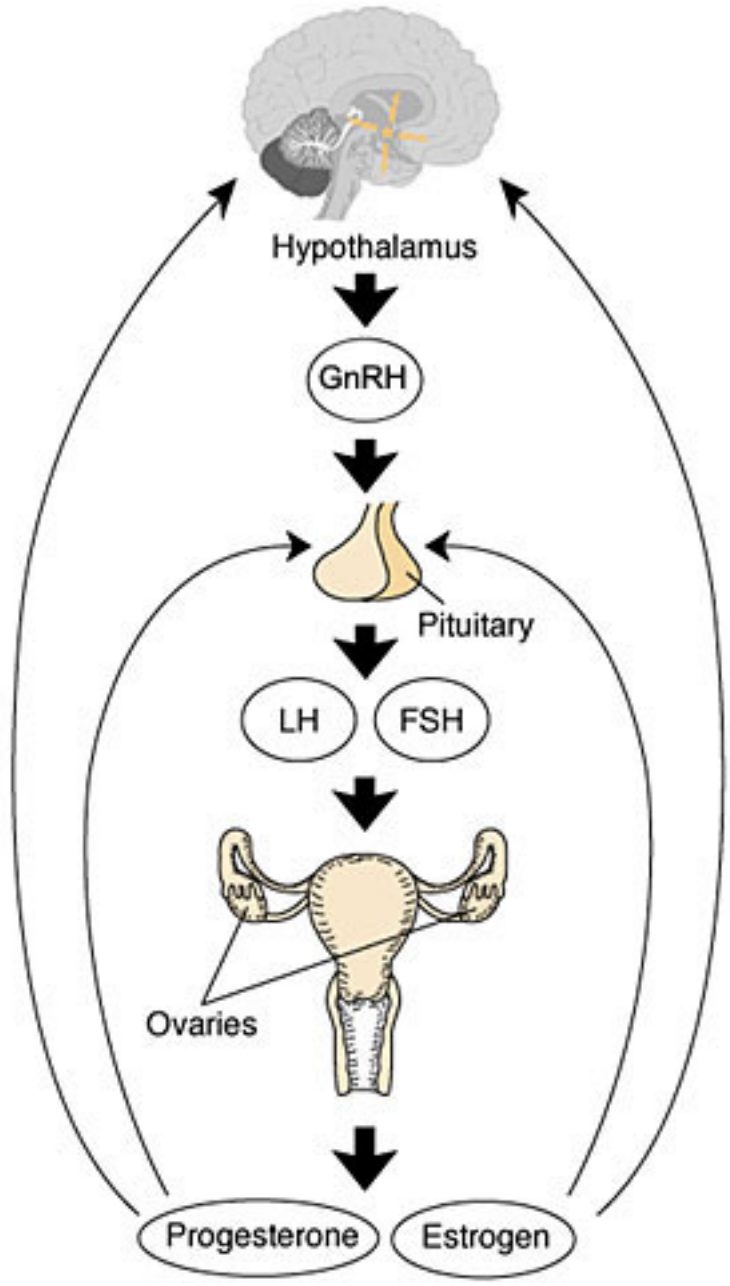

Female HPG Axis

Sex Differences in Adult and Developing Brains

Brains of males and females differ

- in regions specialized for reproduction
- in other regions (controlling cognition, etc) where sex differences are not necessarily expected
- differentially susceptible to neurological and psychiatric disease

2 sources of sexually dimorphic information

- complement of sex chromosome genes
- mix of gonadal hormones

- not known significance of brain sex differences

- transient sex differences in gene expression in developing brains may cause permanent differences in brain structure

Abnormalities

Human genital abnormalities are currently described as "Disorders of Sex Development" (DSD).

Include: chromosomal, gonadal dysfunction, tract abnormalities, external genitalia and gonadal descent.



Human genital development critical periods

Sex Reversal

- Where chromosomal sex does not match phenotypic sex i.e. XX males or XY females.

XX males - usually caused by a transfer of some Y chromosome DNA onto the X chromosome

- Gonads develop as testes, everything looks normal internally and externally but infertile due to a failure of spermatogenesis
- Similar to Kleinfelters syndrome (XXY)

XY females - usually steroidal origin

- Main cause is Androgen Insensitivity Syndrome (AIS) Complete (CAIS) Partial (PAIS) and Mild (MAIS) usually caused by mutations of the gene encoding the androgen receptor *AR* gene located on the X chromosome
- 5-alpha-reductase deficiency - again leads to a lack of complete steroidal induction of external genitalia
- Rare mutations in key sex determining genes including deletion or mutations of *SRY*

Links: genital abnormalities

Congenital Adrenal Hyperplasia

- impairment of cortisol production by the adrenal cortex, is one of the most common causes of DSD genitalia at birth.
- depending upon the synthesising enzyme affected a range of genital and hypertensive abnormalities can occur in the 2 sexes.

Links: congenital adrenal hyperplasia | adrenal | Genital CAH Abnormalities

Cryptorchidism

- abnormality of either unilateral or bilateral testicular descent, occurring in up to 30% premature and 3-4% term males.
- descent may complete postnatally in the first year, failure to descend can result in sterility.

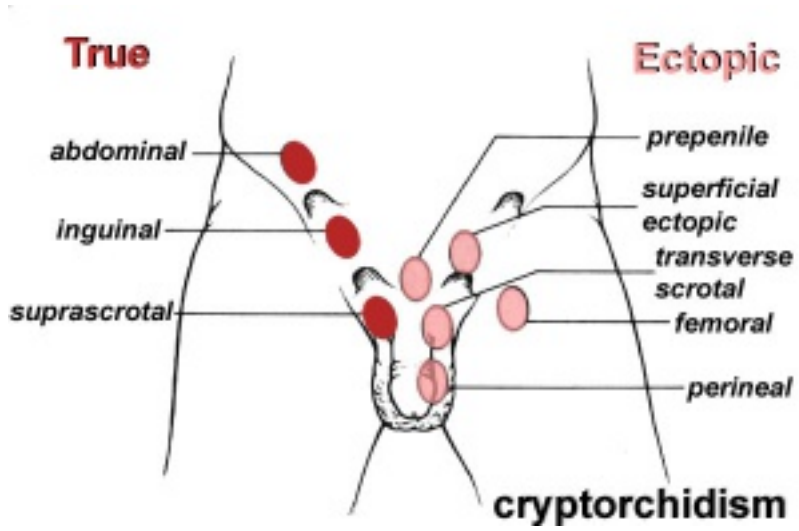

Cryptorchidism

Testis descent is thought to have 2 phases:

1. transabdominal descent - dependent on insulin-like hormone 3 (INSL3).
2. inguinoscrotal descent - dependent on androgens.

Undescended Ovaries

- reasonably rare gonad abnormality, often detected following clinical assessment of fertility problems and may also be associated with other uterine malformations (unicornuate uterus).
- Due to the relative positions of the male (external) and female (internal) gonads and the pathways for their movement, failure of

gonad descent is more apparent and common in male cryptorchidism than female undescended ovaries.

Hydrocele

- **Male Hydrocele** is a fluid-filled cavity of either testis or spermatic cord, where peritoneal fluid passes into a patent processus vaginalis.
- **Female Hydrocele** is a similar, but rarer, fluid-filled cavity occuring in the female as a pouch of peritoneum extending into the labium majorum (canal of Nuck).

Tract Abnormalities

Many different forms

- Uterine: associated with other anomolies, unicornuate uterus
- Vagina: agenesis, atresia
- Ductus Deferens: Unilateral or bilateral absence, failure of mesonephric duct to differentiate

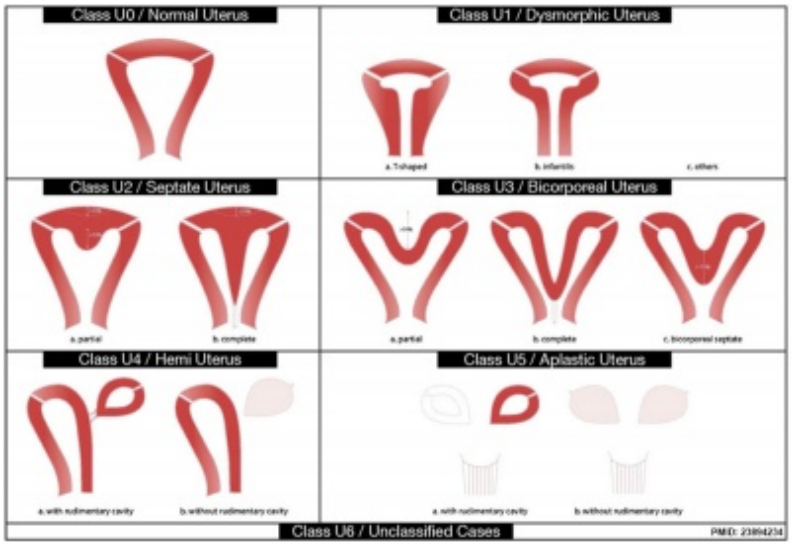	
Uterine abnormalities	Unicornate uterus

Uterine Duplication (uterus didelphys, double uterus, uterus didelphis) A rare uterine developmental abnormality where the paramesonephric ducts (Mullerian ducts) completely fail to fuse generating two separate

uterus parts each connected to the cervix and having an ovary each.

Septate Uterus

Cervical: cervical agenesis, cervical duplication

Vaginal: Mayer-Rokitansky syndrome (MRK anomaly, Rokitansky-Küster-Hauser syndrome, RKH syndrome, RKH) congenital absence of the vagina, dyspareunia, vaginal agenesis.

External Genitalia - Hypospadia

• most common penis abnormality (1 in 300) from a failure of male urogenital folds to fuse in various regions and resulting in a proximally displaced urethral meatus. • The cause is unknown, but suggested to involve many factors either indivdually or in combination including: familial inheritance, low birth weight, assisted reproductive technology, advanced maternal age, paternal subfertility and endocrine-disrupting chemicals. Infants with hypospadias should not undergo circumcision.	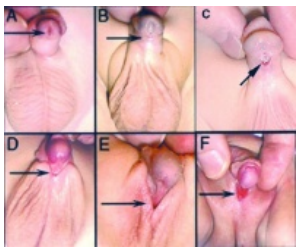 Hypospadia classifications

Movies

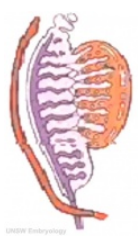	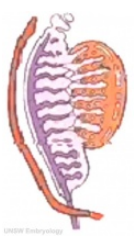	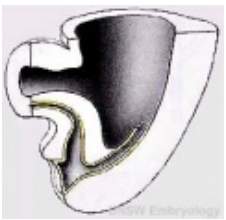		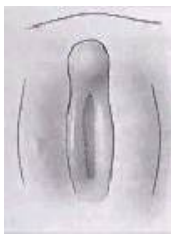		
Ovary	**Testis**	**Urogenital Septum**	**Female External**	**Male External**	**Uterus**	**Test Desc**
Page | Play	Page | Play	Page | Play	Page | Play	Page | Play	Page | Play	Page Play

Mouse Primordial Germ Cell Migration		

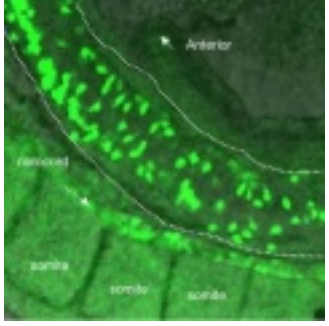	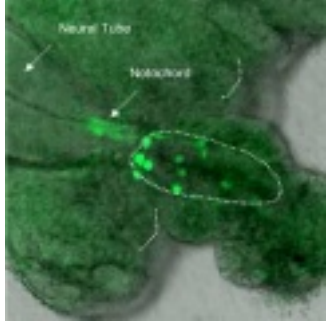	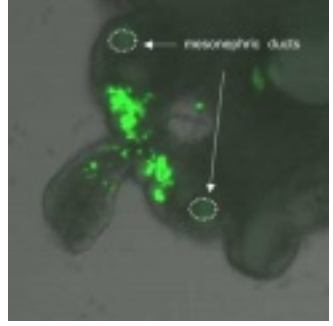
Germ Cell E9.0	**Germ Cell E9.5**	**Germ Cell E10.5**
Page | Play	Page | Play	Page | Play

References

1. ↑ Cunha GR, Kurita T, Cao M, Shen J, Robboy S & Baskin L. (2017). Molecular mechanisms of development of the human fetal female reproductive tract. *Differentiation , 97*, 54-72. PMID: 29053991 DOI.
2. ↑ Cai Y. (2009). Revisiting old vaginal topics: conversion of the Müllerian vagina and origin of the "sinus" vagina. *Int. J. Dev. Biol. , 53*, 925-34. PMID: 19598112 DOI.

Reviews

Roly ZY, Backhouse B, Cutting A, Tan TY, Sinclair AH, Ayers KL, Major AT & Smith CA. (2018). The cell biology and molecular genetics of Müllerian duct development. *Wiley Interdiscip Rev Dev Biol , , .* PMID: 29350886 DOI.

Kim JH, MacLaughlin DT & Donahoe PK. (2014). Müllerian inhibiting substance/anti-Müllerian hormone: A novel treatment for gynecologic tumors. *Obstet Gynecol Sci , 57*, 343-57. PMID: 25264524 DOI.

Feingold KR, Anawalt B, Boyce A, Chrousos G, Dungan K, Grossman A, Hershman JM, Kaltsas G, Koch C, Kopp P, Korbonits M, McLachlan R, Morley JE, New M, Perreault L, Purnell J, Rebar R, Singer F, Trence DL, Vinik A, Wilson DP, Rey R, Josso N & Racine C. (2000). Sexual Differentiation. *, , .* PMID: 25905232

Wilhelm D, Palmer S & Koopman P. (2007). Sex determination and gonadal development in mammals. *Physiol. Rev. , 87*, 1-28. PMID:

17237341 DOI.

- Historic - **Text-Book of Embryology**. Bailey, F.R. and Miller, A.M. (1921). New York: William Wood and Co. Chapter 15. The Genital Glands

BGDB: Lecture - Gastrointestinal System | Practical - Gastrointestinal System | Lecture - Face and Ear | Practical - Face and Ear | Lecture - Endocrine | Lecture - Sexual Differentiation | Practical - Sexual Differentiation | Tutorial

Glossary Links

Glossary: A | B | C | D | E | F | G | H | I | J | K | L | M | N | O | P | Q | R | S | T | U | V | W | X | Y | Z | Numbers | Symbols | Term Link