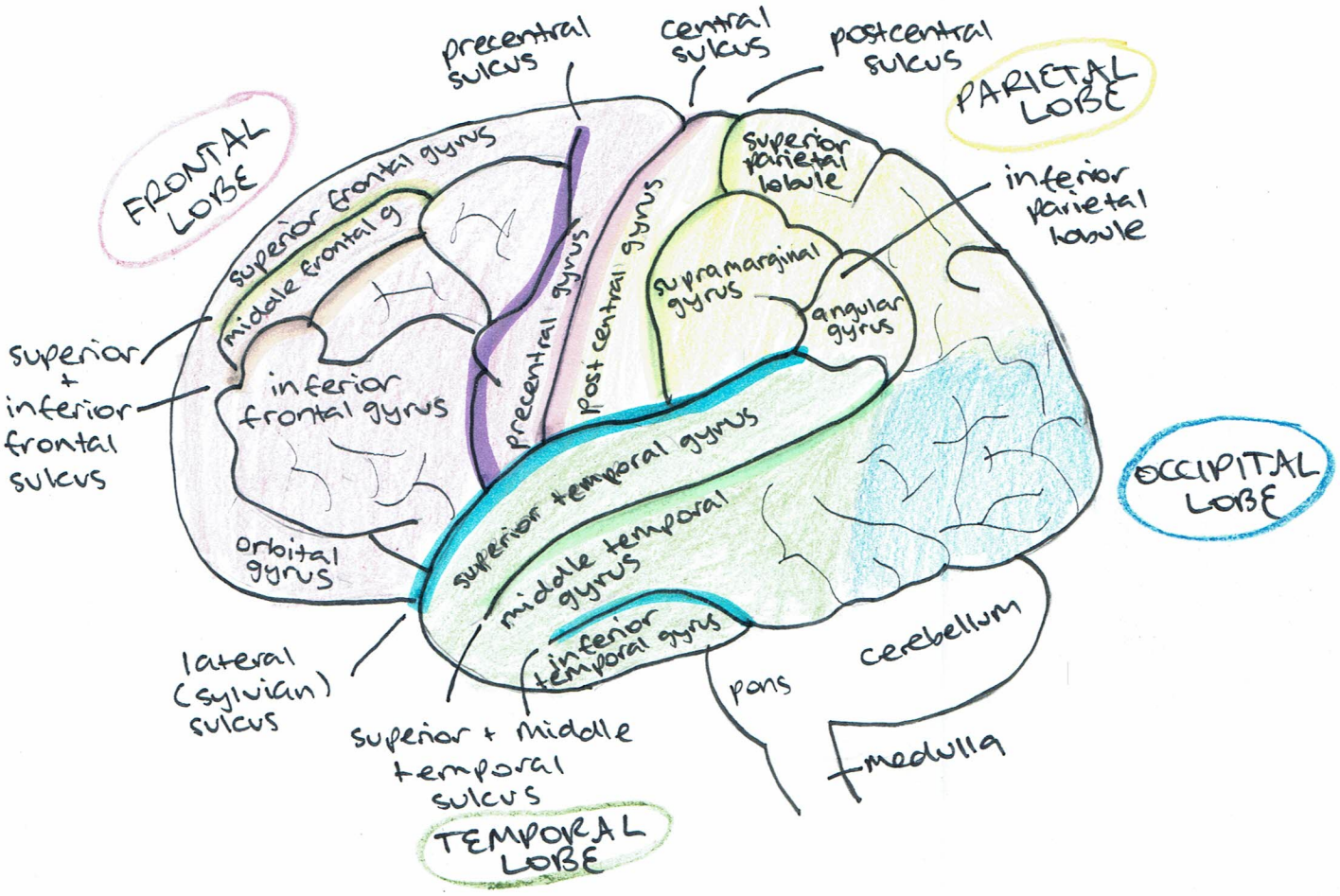
precentral sulcus
central sulcus
postcentral sulcus
PARIETAL LOBE
FRONTAL LOBE
superior frontal gyrus
superior parietal lobule
inferior parietal lobule
middle frontal g
precentral gyrus
post central gyrus
supramarginal gyrus
angular gyrus
superior + inferior frontal sulcus
inferior frontal gyrus
superior temporal gyrus
OCCIPITAL LOBE
orbital gyrus
middle temporal gyrus
inferior temporal gyrus
cerebellum
lateral (sylvian) sulcus
pons
superior + middle temporal sulcus
medulla
TEMPORAL LOBE

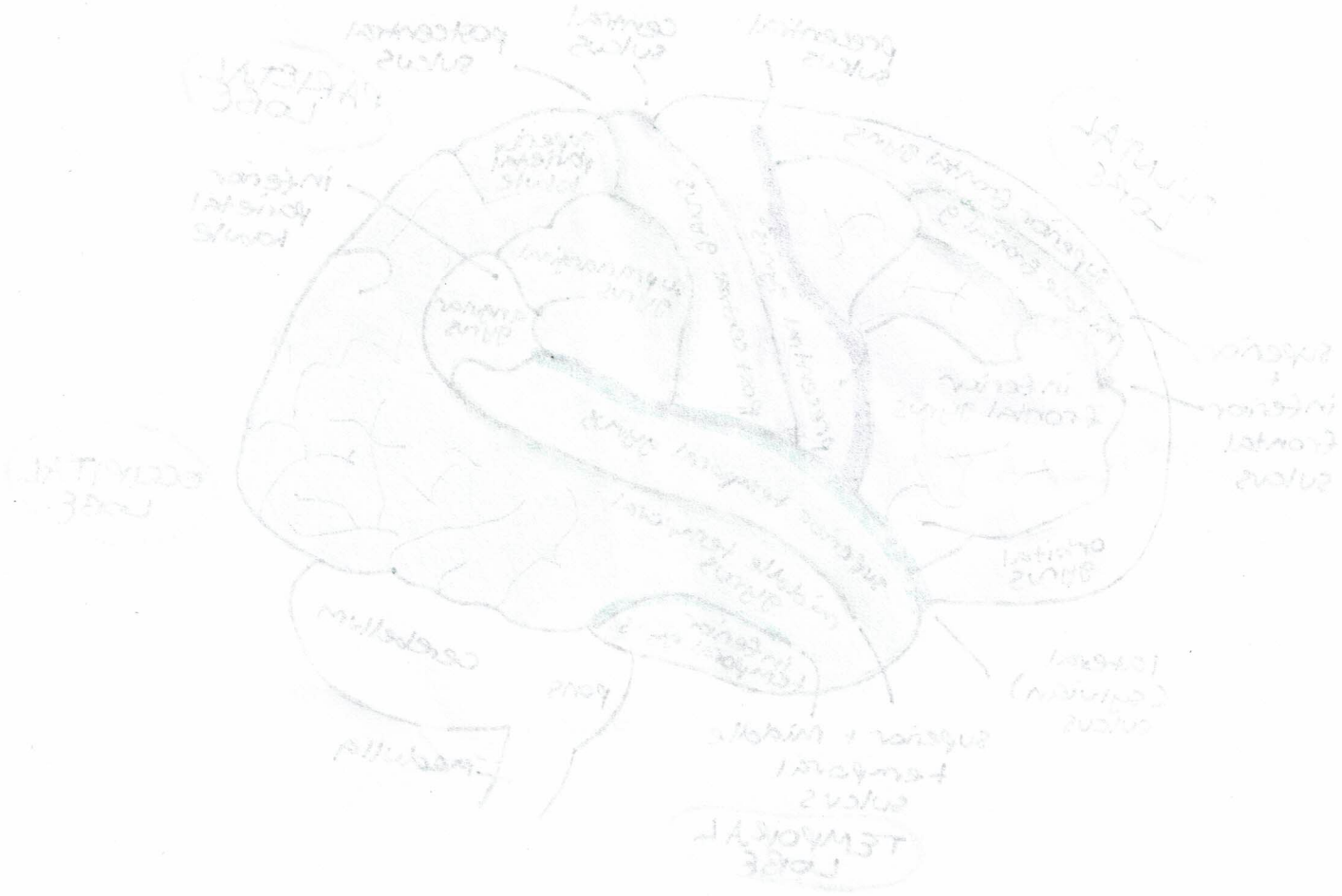
Cerebellum
Pons
Medulla
Superior + middle temporal sulcus
TEMPORAL LOBE
Inferior temporal sulcus
Lateral (sylvian) sulcus
Orbital sulcus
Superior + inferior frontal sulcus
Superior frontal sulcus
Central sulcus
Precentral sulcus
Postcentral sulcus
Intraparietal sulcus
Superior parietal lobule
Inferior parietal lobule
OCCIPITAL LOBE
FRONTAL LOBE
PARIETAL LOBE