

## Practical 1: Lymphoid Tissue & Organs

*Principal Teacher: Dr Mark Hill*

### Objectives

1. Understand the major cell types of blood as they appear in blood smears
2. Understand the histology and organization of lymphoid organs (thymus, spleen, lymph nodes)
3. Understand the histology and organization of lymphoid tissue, particularly that associated with the gastrointestinal tract.

### Resources

#### Virtual Slide Box UNSW - Blood and Lymphoid histology

<http://vslides.unsw.edu.au/VirtualSlideV2.nsf/id/FA8942>

#### UIOW

[http://www.path.uiowa.edu/cgi-bin-pub/vs/fpx\\_browse.cgi?cat=o\\_hemato&div=nlm](http://www.path.uiowa.edu/cgi-bin-pub/vs/fpx_browse.cgi?cat=o_hemato&div=nlm)

#### UNSW Embryology

[http://php.med.unsw.edu.au/embryology/index.php?title=SH\\_Practical\\_-\\_Lymphatic\\_Structure\\_and\\_Organs](http://php.med.unsw.edu.au/embryology/index.php?title=SH_Practical_-_Lymphatic_Structure_and_Organs)

Kierszenbaum, A.L. (2002). Chapter 6; Blood and Hematopoiesis & Chapter 10; Immune- Lymphatic System in **Histology and Cell Biology: An Introduction to Pathology**. (1<sup>st</sup> ed., pp147-175; pp267-298). Philadelphia, Pa. Mosby, Elsevier.

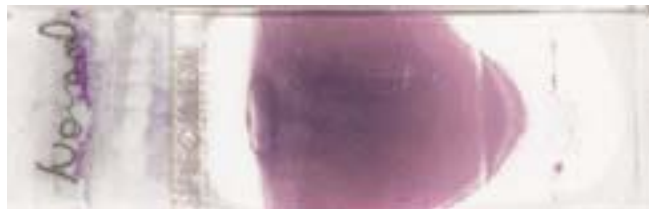### Introduction

This practical class has 2 main parts. The first part will briefly revise the cellular components of blood and their development. The second part will look in more detail at the organs and tissues associated with lymphoid (lymphatic) immune function. The Practical involves studying selected slides from the Virtual Slide Box. Some text in these practical notes modified from Virtual Slidebox Histology. Additional online self-directed learning resources are available from UNSW Embryology page (address above) including external resource and glossary links.

### Blood

The circulating blood is a liquid connective tissue consisting of cells (red and white blood cells), fragments of cells (platelets) and liquid (plasma). The different cell types are all derived from haemopoietic stem cells located in the bone marrow. Red blood cells (RBCs) have a metabolic role, in carrying oxygen to tissues and carbon dioxide to the lungs. White blood cells (WBCs or leukocytes) have a role in the body's defence, and are an important clinical indicator of disease.

#### Virtual Slide Box: 1. Human Blood Smear




Find an area in the smear where the red blood cells are spread out and individual cells can be identified.

Identify: Red blood cells (7-8 um diameter anucleate biconcave disc)

White blood cells: neutrophils, eosinophils, basophils, lymphocytes and monocytes.

(basophils are normally rare). Note the presence or absence of granules, shape of the nucleus and relative cell sizes. Also identify platelets.

**Virtual Slide Box: 2. Bone Marrow Smear**

Do not attempt to identify all the cells in the bone marrow smear, but compare its appearance with that of the blood smear.

Hematopoiesis is the process of blood cell differentiation and occurs mainly in the bone marrow. This bone marrow smear will contain a large number of differentiating blood cells: band cells and normoblasts. The largest cells visible are megakaryocytes, which are responsible for platelet production.

Lymphocyte differentiation begins in the bone marrow and continues in central lymphoid organs (bone marrow - B cells and thymus - T cells), then in the peripheral lymphoid organs (lymph nodes, spleen).

**Questions**

1. What is the normal blood haematocrit range?
2. Does this haematocrit differ for male/female?
3. What is the function of the various blood cells?
4. Which tissues have very large numbers of white blood cells and why?
5. In histology tissue sections which blood vessel (artery/vein) is more likely to contain blood cells?

**Lymphoid Tissue**

Lymphoid (or lymphatic) tissues consist of dense accumulations of lymphocytes in many different body regions, typically at sites that provide a route of entry of pathogens or sites that are prone to infections. Depending on their precise location these lymphoid tissues may be epithelia associated and referred to as mucosa-associated lymphoid tissue (MALT) or bronchus-associated lymphoid tissue (BALT). The gastrointestinal tract tonsils and Peyer's patches are examples of mucosa-associated lymphoid tissues.

**Virtual Slide Box: 3. Infant Thymus**

Section of a thymus lobe of an infant.

The thymus changes its histological appearance from infant to puberty to adult, in a process called involution (replacement of cortical lymphoid tissue by adipose tissue) and there is also an increase in the size of thymic corpuscles.

At low magnification: note the surrounding connective tissue capsule along the surface. The thymus is divided into many smaller lobules by connective tissue septa extending inward from the capsule. These lobules have a cortex (dark staining) and a medulla (pale staining). The interlobular septa do not penetrate into the medulla, and lobules are joined together in the medulla. Some septa may carry blood vessels and efferent lymphatic vessels.

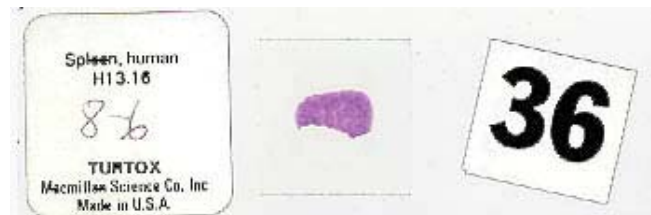At high magnification: **Cortex** has a dense layer of closely packed cells (developing and maturing T lymphocytes, thymocytes). **Medulla** consist of an eosinophilic central mass surrounded by concentrically arranged epithelial cells (Hassall's corpuscles). Do not confuse them with blood vessels.

Compare the appearance of the infant with the adult thymus (below).

**Virtual Slide Box: 4. Adult Thymus**



**Virtual Slide Box: 5. Spleen**



The spleen in fetal life is a site for blood formation (hematopoiesis). The adult spleen has 2 main functions: immune, as a major site of antigen presentation for the circulation system and removal of aged erythrocytes from the circulation. The spleen has a dense connective tissue capsule, which contains trabeculae running into the interior of the spleen forming incomplete compartments (as in the thymus). The stroma is mainly composed of reticular connective tissue and cells. There is a Hilum, which contains arteries and veins, but unlike a lymph node, there are no lymphatics. It should also be noted that the spleen cannot be divided into a medulla and cortex, which helps differentiate it from the thymus or a lymph node.

The spleen is a major site of antigen presentation for the circulation system, and in fetal life, it is a site for hematopoiesis. It also functions in removing senescent erythrocytes from the circulation. The spleen is surrounded by a dense connective tissue capsule, which contains trabeculae running into the interior of the spleen forming incomplete compartments. The stroma is mainly composed of reticular connective tissue and cells. There is a Hilum, which contains arteries and veins, but unlike a lymph node, there are no lymphatics. It should also be noted that the spleen cannot be divided into a medulla and cortex, which helps differentiate it from the thymus or a lymph node.

Identify connective tissue capsule, trabeculae, white pulp, red pulp, lymphatic nodules, and central arterioles.

The two main interior divisions of the spleen are white and red pulp. White pulp consists of a sheath of lymphoid cells surrounding an eccentrically located central arteriole. The T lymphocytes immediately surrounding the central arteriole are referred to as periarterial lymphatic sheaths (PALS). Surrounding that is a layer of peripheral white pulp (PWP), which is composed of B lymphocytes. Antigen enters the white pulp from the central arteriole, activates the PALS, which then activates the PWP. The marginal zone on the periphery of the white pulp is believed to be an important area for trapping antigens and initiation of immune responses. Both lymphocytes and macrophages are present in the marginal zone.

The red pulp consists of splenic cords of Billroth and splenic sinusoids. The splenic cords of Billroth contain reticular cells, macrophages, lymphocytes, plasma cells, and erythrocytes. The splenic sinusoids are modified capillaries with an exceptionally wide lumen and spaces in the wall to allow cells to squeeze in and out. Macrophages are also able to extend processes into the sinusoid, allowing them to identify senescent red blood cells.

Blood enters the spleen via the splenic artery at the hilum. The blood then travels through the trabecular arteries, central arterioles, penicillar arterioles, capillaries, splenic sinusoids, trabecular veins, and finally out the splenic vein at the hilum.

**Virtual Slide Box: 5. Spleen****(monkey silver stain)**

Spleen silver-stained to show connective tissue reticular fibers (black), compare this with the silver-stained lymph node.

**Virtual Slide Box: 6. Lymph Node**

Lymph nodes are peripheral lymphoid organs involved in helping the body defend against foreign organisms. Lymph, which contains antigen and antigen presenting cells, flows from local tissue lymphatic vessels and enters the subcapsular sinus. The lymph then filters through the intermediate sinuses, into the medullary sinuses, and finally out the efferent lymphatic vessels at the hilum before it is returned to the circulation. B and T cells are numerous in the lymph node, and they enter through afferent arteries, enter the lymphoid tissue across specialized vessels called high-endothelial venules, and return to the circulation via efferent veins.

Identify the following features: the connective tissue capsule, the trabeculae, the subcapsular sinus (lying immediately below the capsule), the intermediate sinus (lying next to a trabecula), outer cortex (composed of lymphatic nodules/follicles), the inner cortex (non-nodular area between outer cortex and medulla) and the medulla (with medullary cords and medullary sinuses).

**Virtual Slide Box: 7. Lymph Node (silver stain)**

Lymph node silver stained to show connective tissue reticular fibers (black).

Identify reticular fiber distribution in: capsule, trabeculae, subcapsular sinuses, intermediate sinuses, lymphoid nodules, the inner cortex, and the medulla.

**Virtual Slide Box: 8. Lingual tonsil (tongue)**

The lingual tonsils are numerous small tonsils located at the base of the tongue. They are covered by a stratified squamous epithelium, but are not enclosed by a capsule. Salivary glands and skeletal muscle are directly adjacent to the tonsil.

**Virtual Slide Box: 9. Pharyngeal tonsil**



Closely packed lymph nodules comprise the outer portion of this organ. The pharyngeal tonsil is covered with a pseudostratified columnar epithelium with cilia (typical of respiratory tract).

**Virtual Slide Box: 10. Appendix**



The appendix (vermiform appendix) anatomy is as a finger-like structure that arises from the cecum. The length (2.5-13 cm) is longer in both infants and children and also has more abundant lymphatic tissue in early life. The wall structure is similar to the small intestine (though with no villi), nor plicae circularis.

Lymph nodules surround the lumen of the gastrointestinal tract and extend from the mucosa into the submucosa. Note in this section most of the muscularis mucosa has been obliterated by lymphatic invasion.

**Questions**

1. What is the difference between stroma and parenchyma?
2. Which cells make reticular fibers?
3. Why are lymphoid tissues associated with the gastrointestinal tract and respiratory tissues?
4. What is an antigen and what does it produce in the immune system?
5. Where can tonsillar tissue be found in the gastrointestinal tract?

## Practical 2: Group Project: Introducing SPSS

**Principal Teacher: Dr Rachel Thompson**

### ***Aims***

- To learn the basics of SPSS data handling and analysis
- To clean the data in the old dataset and practice handling and analysing the data

### ***Key Concepts***

Parametric and non-parametric statistics, correlation, chi-square, t-test

### ***Key References***

UCLA Academic Technical Services. Introduction to SPSS: Analyzing Data. Part 1.  
<http://www.ats.ucla.edu/stat/spss>

***Practical Notes for this class are available online from the QMP Blackboard course or directly from***  
[http://web.med.unsw.edu.au/QMP/SPSSDataHandling/DataPrac\\_Objectives.htm](http://web.med.unsw.edu.au/QMP/SPSSDataHandling/DataPrac_Objectives.htm)