Early Development of the Ectoderm

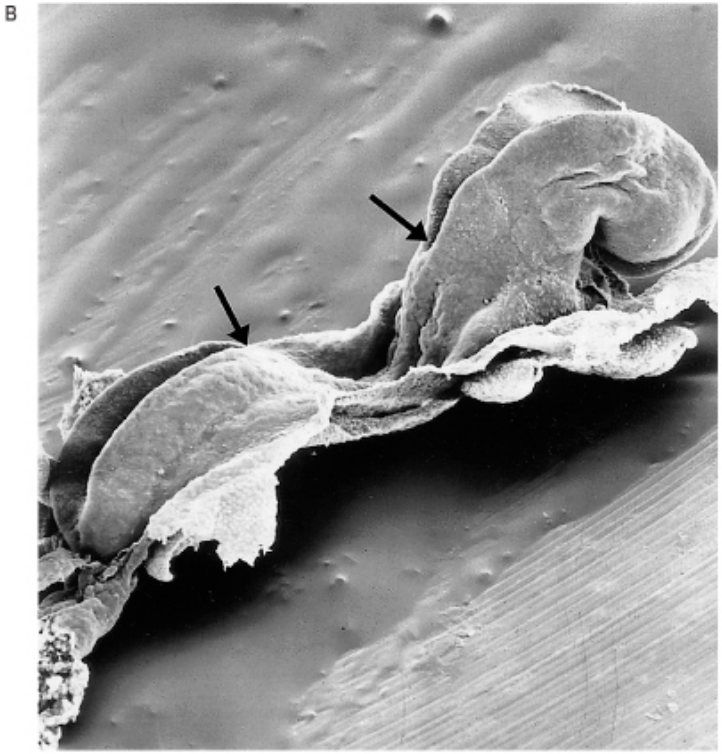

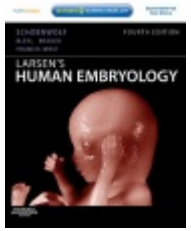

Resources:
http://php.med.unsw.edu.au/embryology/
Larsen's Human Embryology
The Developing Human: Clinically Oriented Embryology



Dr Annemiek Beverdam – School of Medical Sciences, UNSW
Wallace Wurth Building Room 234 – A.Beverdam@unsw.edu.au

Lecture overview
Early Development of the Ectoderm

Gastrulation and Embryonic Folding

Neurulation

Early Development of the Nervous System

Neural Crest

Epidermis Development

Ectodermal placodes

Neural Tube Defects

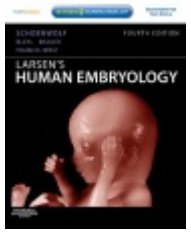

Resources:
http://php.med.unsw.edu.au/embryology/
Larsen's Human Embryology
The Developing Human: Clinically Oriented Embryology

Dr Annemiek Beverdam – School of Medical Sciences, UNSW
Wallace Wurth Building Room 234 – A.Beverdam@unsw.edu.au

Week 3: gastrulation:

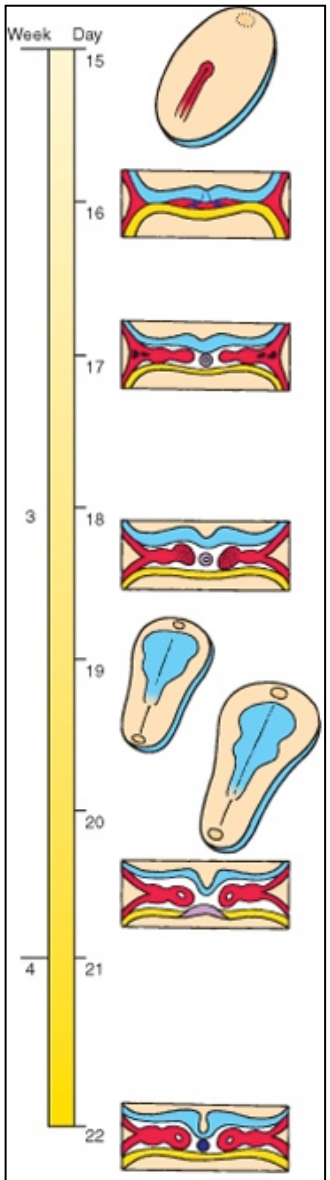

Schoenwolf et al: Larsen's Hu
Copyright © 2008 by Church

Primitive streak and node
Ingression of epiblast cells: EMT transition
Generation of endoderm
Generation of mesoderm
Generation of ectoderm
Oropharyngeal and cloacal membrane

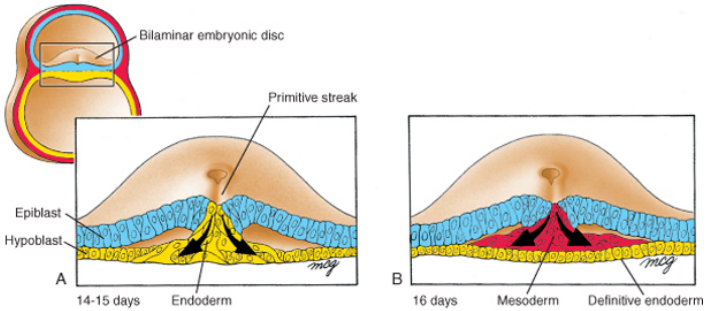

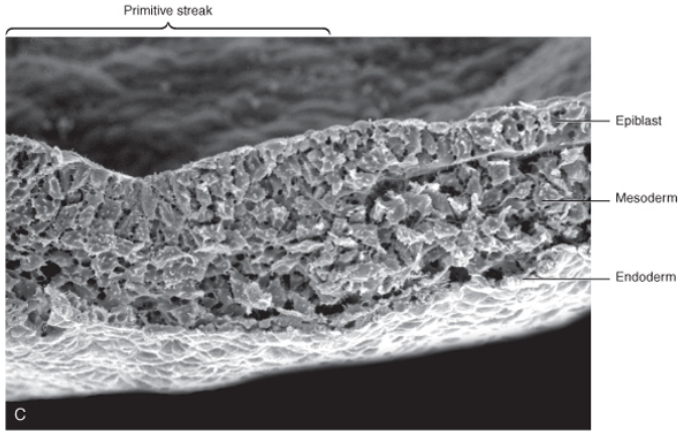

Schoenwolf et al: Larsen's Human Embryology, 4th Edition.

Week 3: Gastrulation

Epiblast forms 3 germ layers:
- Ectoderm: epithelium (previous epiblast)
- Mesoderm: mesenchymal layer (embryonic connective tissue)
- Endoderm: epithelium

Hypoblast:
- replaced by definitive endoderm

3 body axes:
- Anteroposterior or cranial to caudal body axis
- Dorsoventral body axis
- Left-Right body axis

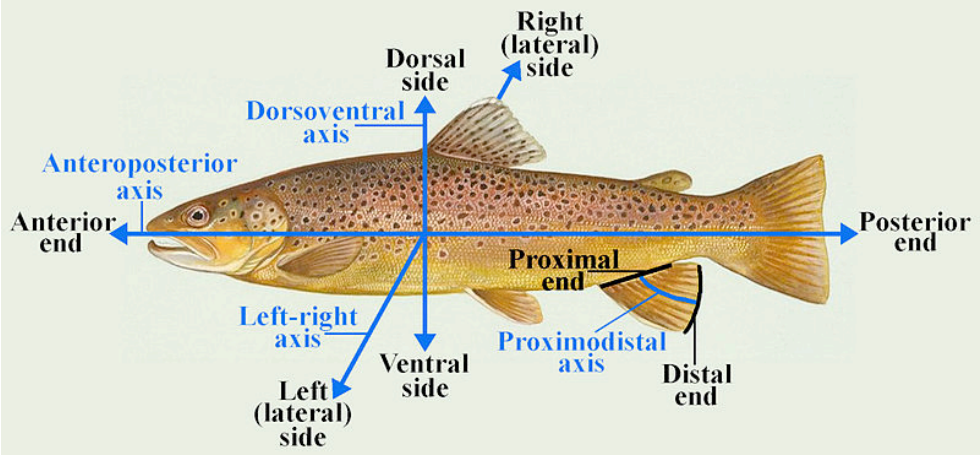

Embryonic development:

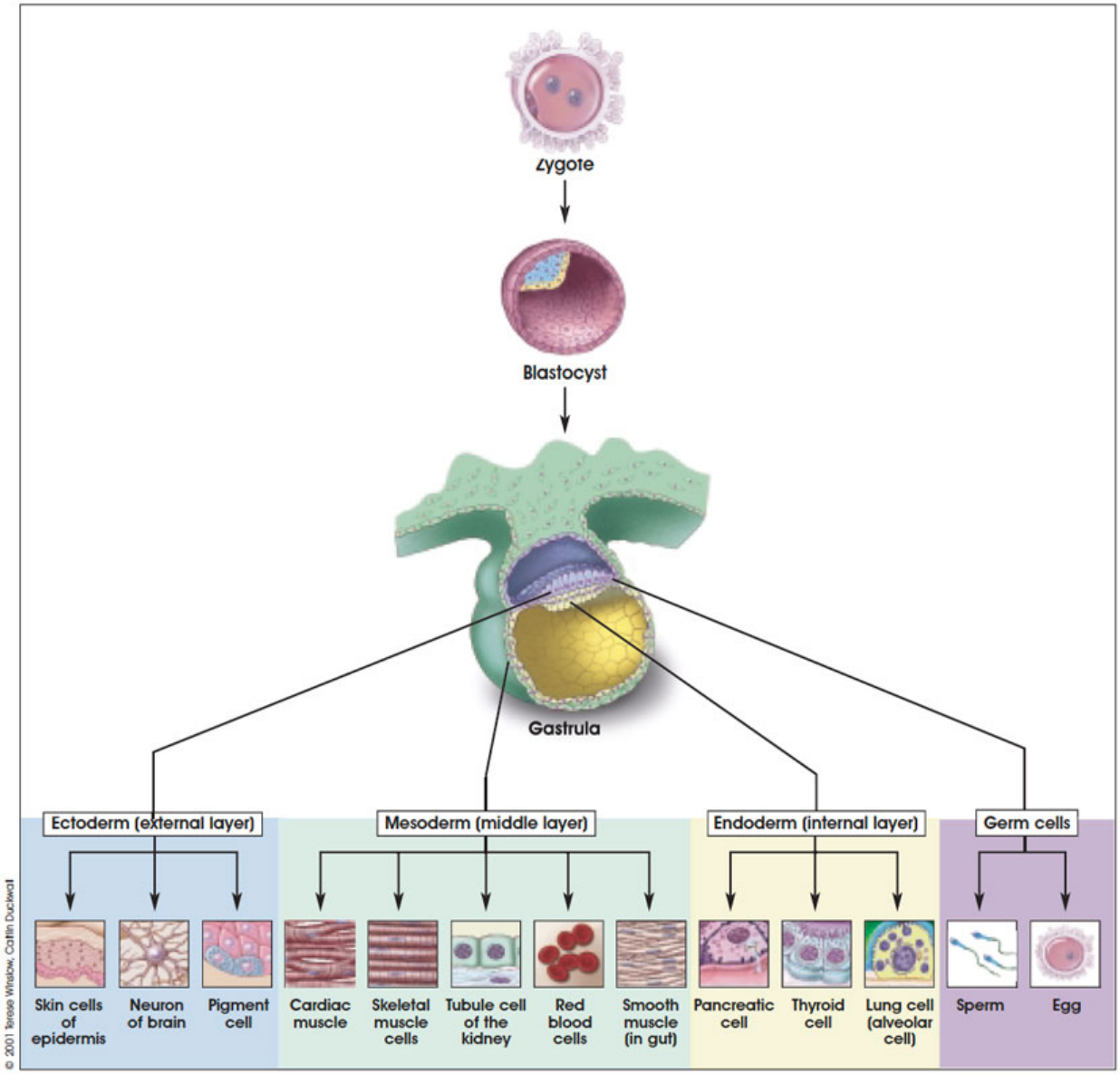

3 weeks

37 weeks

End product gastrulation:

Trilaminar embryo

Ectoderm *(Neural crest)*
brain, spinal cord, eyes, *peripheral nervous system*
epidermis of skin and associated structures,
melanocytes, cranial connective tissues (dermis)

Mesoderm
musculo-skeletal system, limbs,
connective tissue of skin and organs,
urogenital system, heart, blood cells

Endoderm
epithelial linings of gastrointestinal, liver, pancreas,
thyroid and respiratory tracts

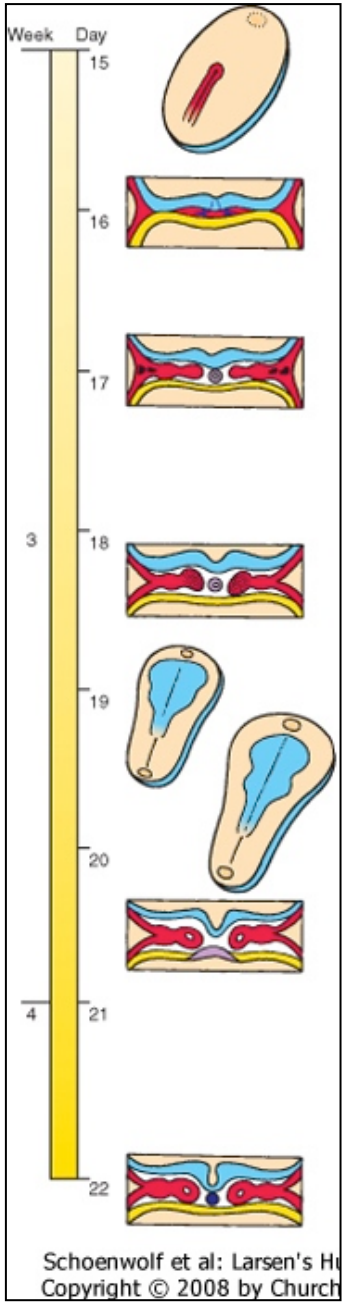

Embryo folding

Generation of primitive gut
Neural plate and neural tube

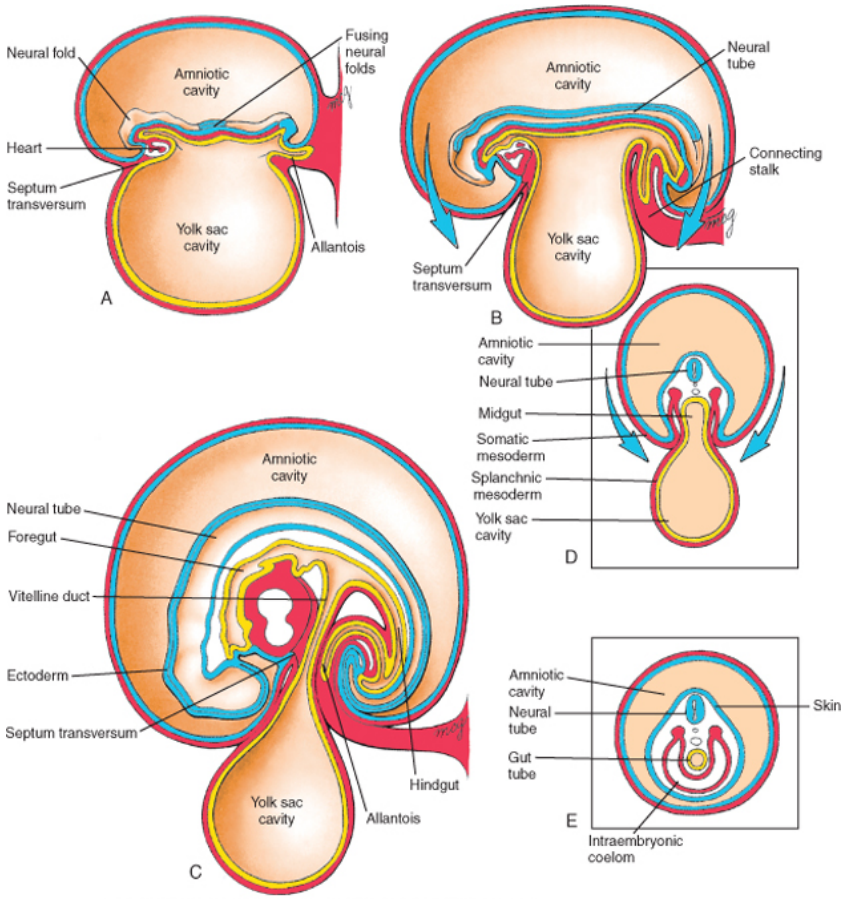

http://php.med.unsw.edu.au/embryology/images/2/27/Week3_folding.mp4

Early ectoderm development:

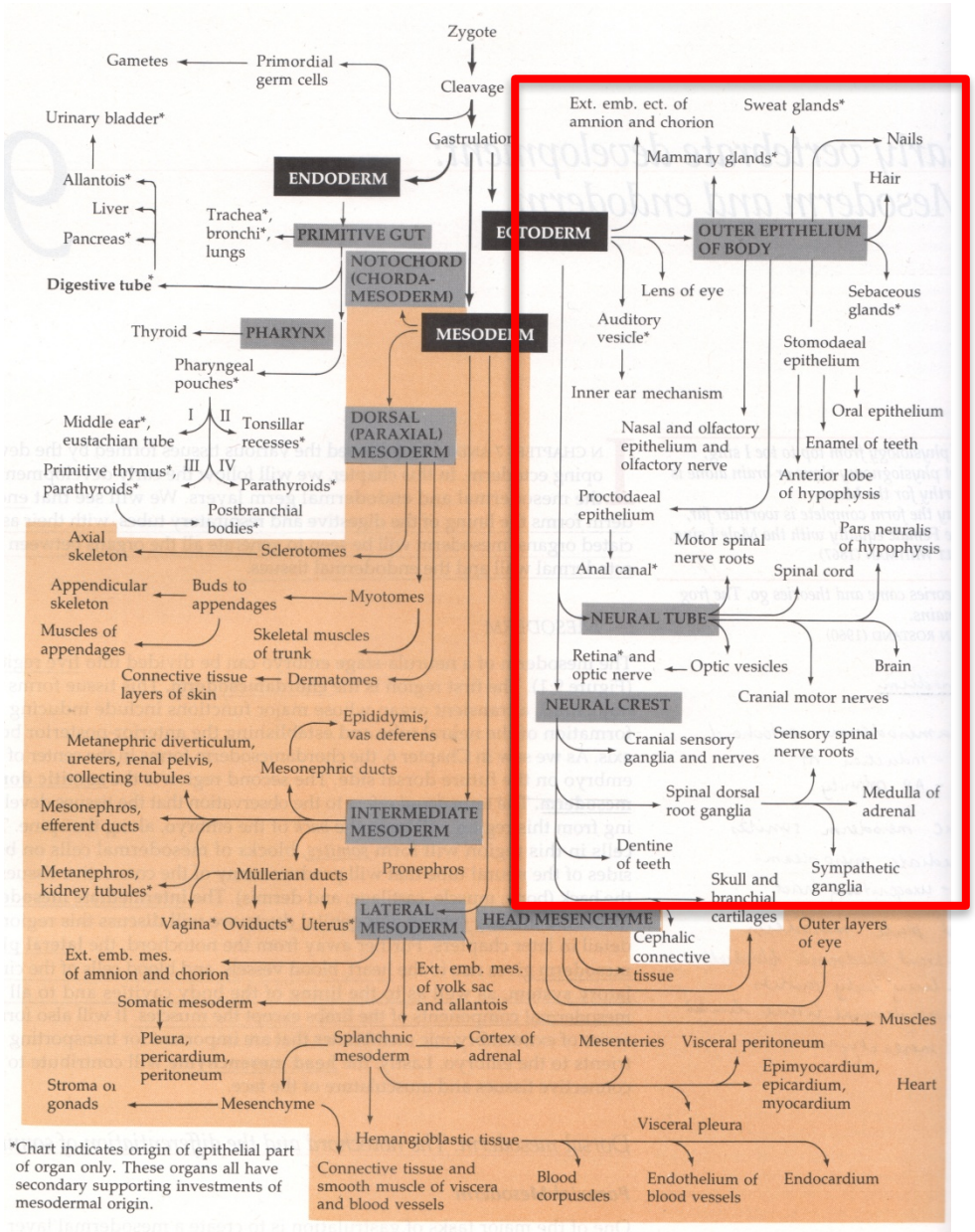

Page 342
S.F. Gilbert
Developmental Biology
5th edition

Ectoderm

Midplate ectoderm: nervous system and neural crest

Lateral ectoderm: surface epidermis

Ectodermal placodes



Midplate Ectoderm

Neural induction by the primitive node
Neural plate = neuroepithelium
Neural plate gives rise to the CNS and the neural crest
Neural groove

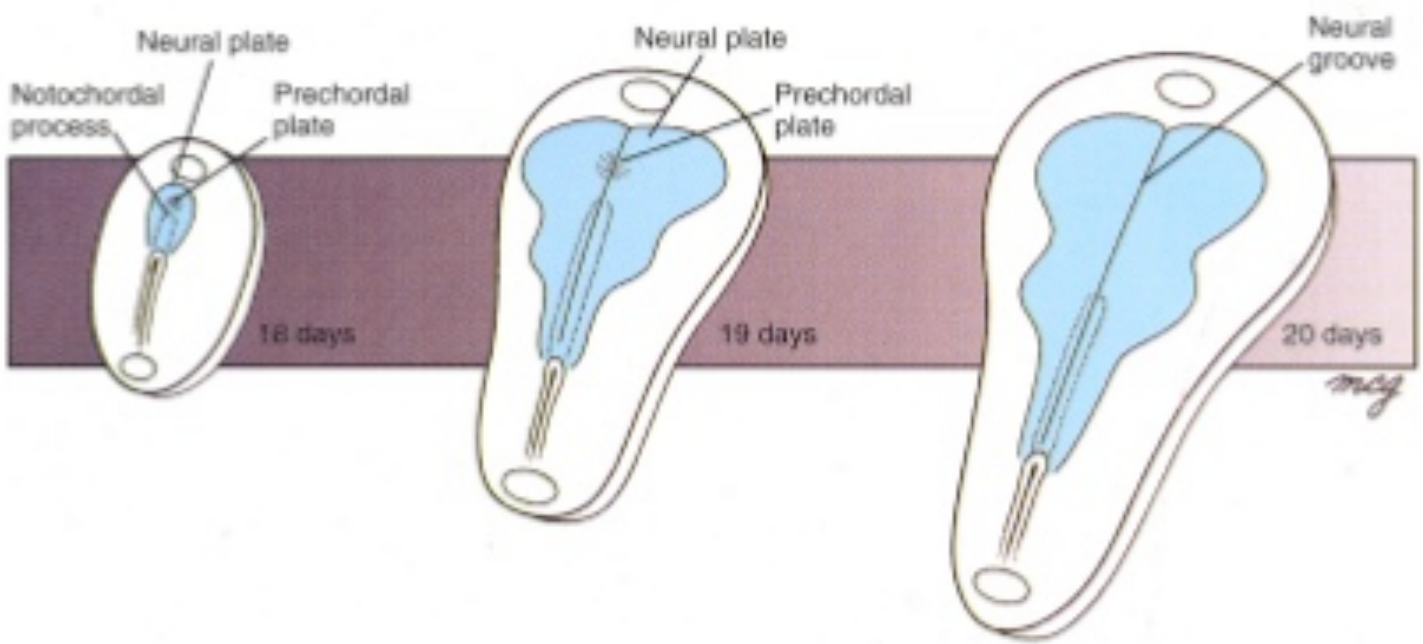

Neurulation
Midplate ectoderm

<u>4 main events</u>:
-1 neural plate formation
-2 shaping of the neural plate
-3 bending of the neural plate
-4 closure of the neural groove

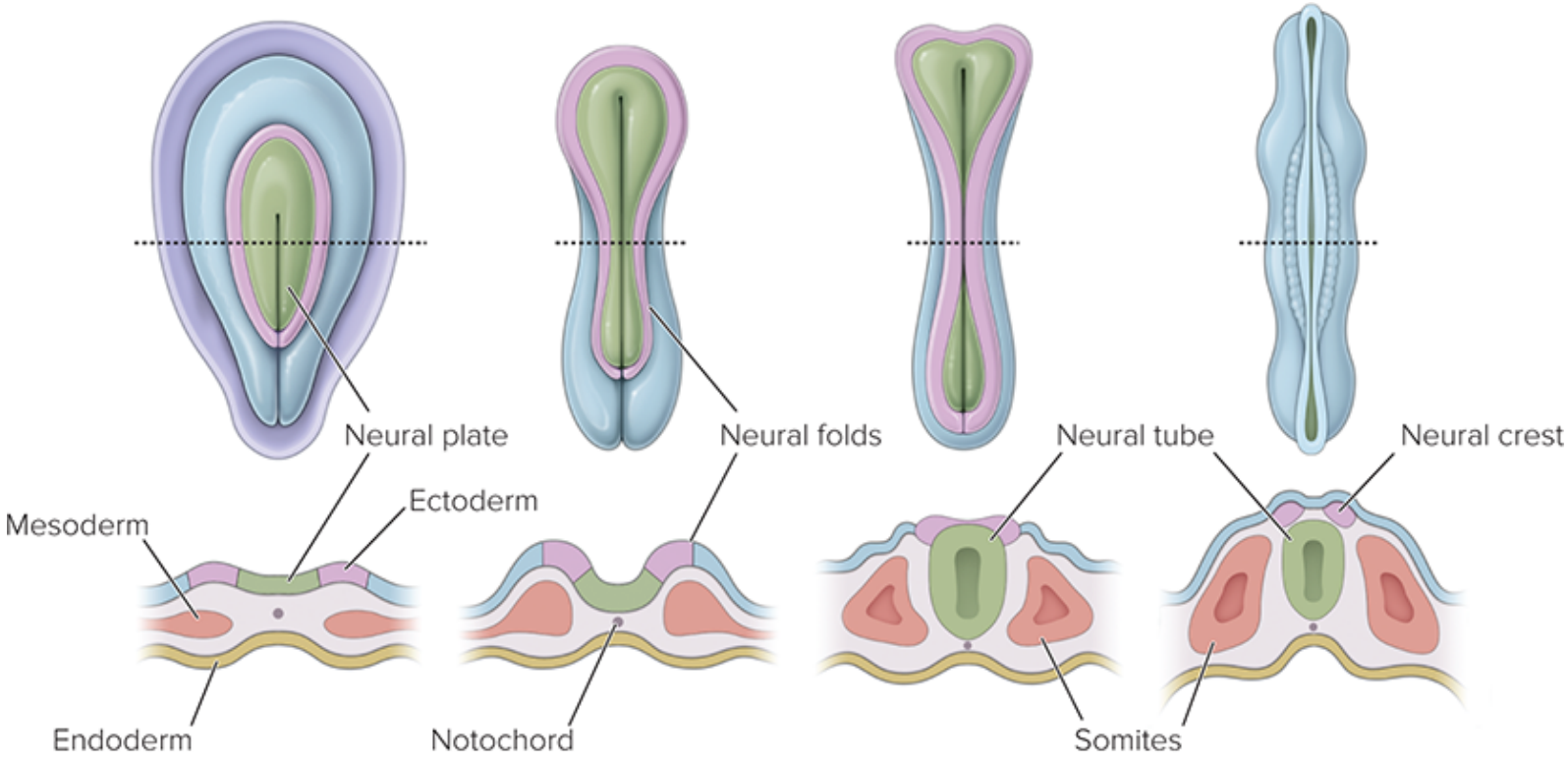

Source: Deborah S. Nichols-Larsen, Deborah A. Kegelmeyer, John A. Buford, Anne D. Kloos, Jill C. Heathcock, D. Michele Basso: *Neurologic Rehabilitation: Neuroscience and Neuroplasticity in Physical Therapy Practice*
www.accessphysiotherapy.com

Neurulation
Midplate ectoderm

The neural tube zips up from center towards both ends
Cranial and caudal neuropores
Closure of caudal neuropore completes neurulation

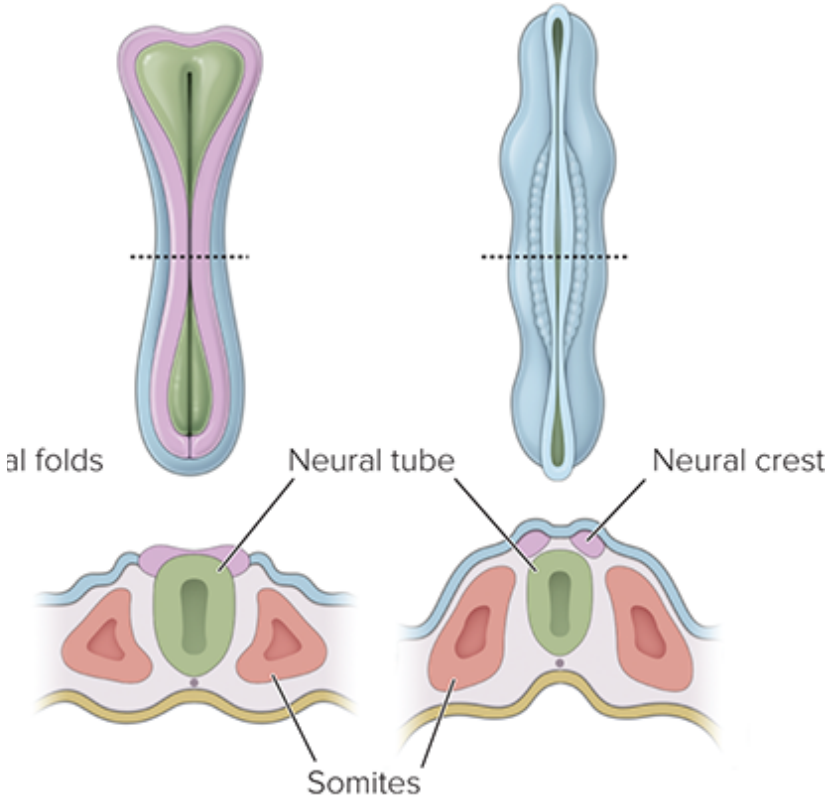

Neurulation

Midplate ectoderm

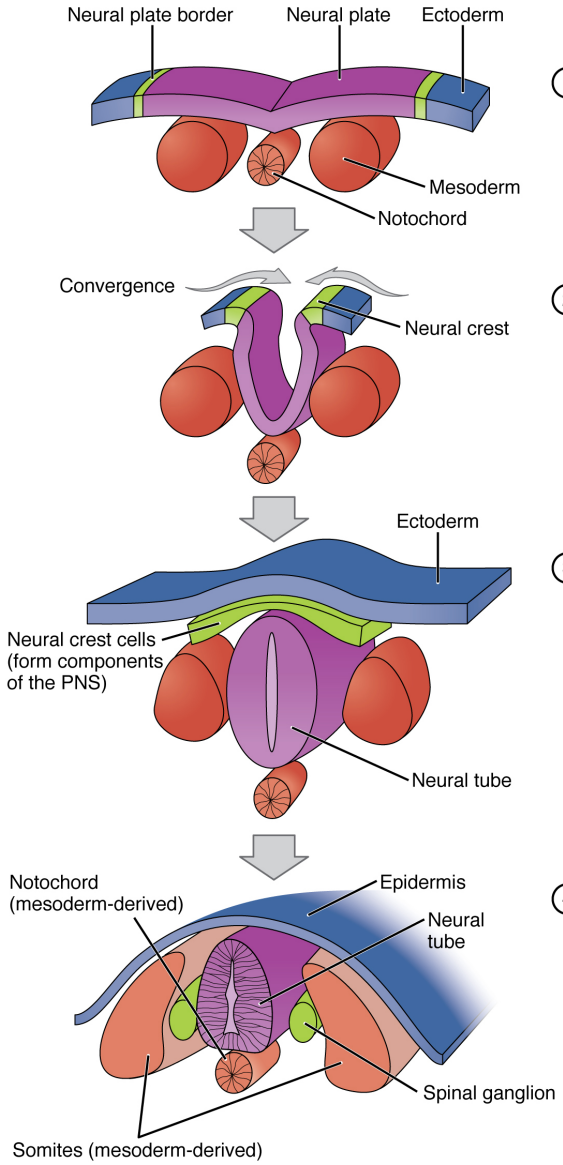

1. Neuroectodermal tissues differentiate from the ectoderm and thicken into the neural plate. The neural plate border separates the ectoderm from the neural plate.

2. The neural plate bends dorsally, with the two ends eventually joining at the neural plate borders, which are now referred to as the neural crest.

3. The closure of the neural tube disconnects the neural crest from the epidermis. Neural crest cells differentiate to form most of the peripheral nervous system.

4. The notochord degenerates and only persists as the nucleus pulposus of the intervertebral discs. Other mesoderm cells differentiate into the somites, the precursors of the axial skeleton and skeletal muscle.

Ectoderm

Midplate ectoderm: nervous system and neural crest
Lateral ectoderm: surface epidermis
Ectodermal placodes

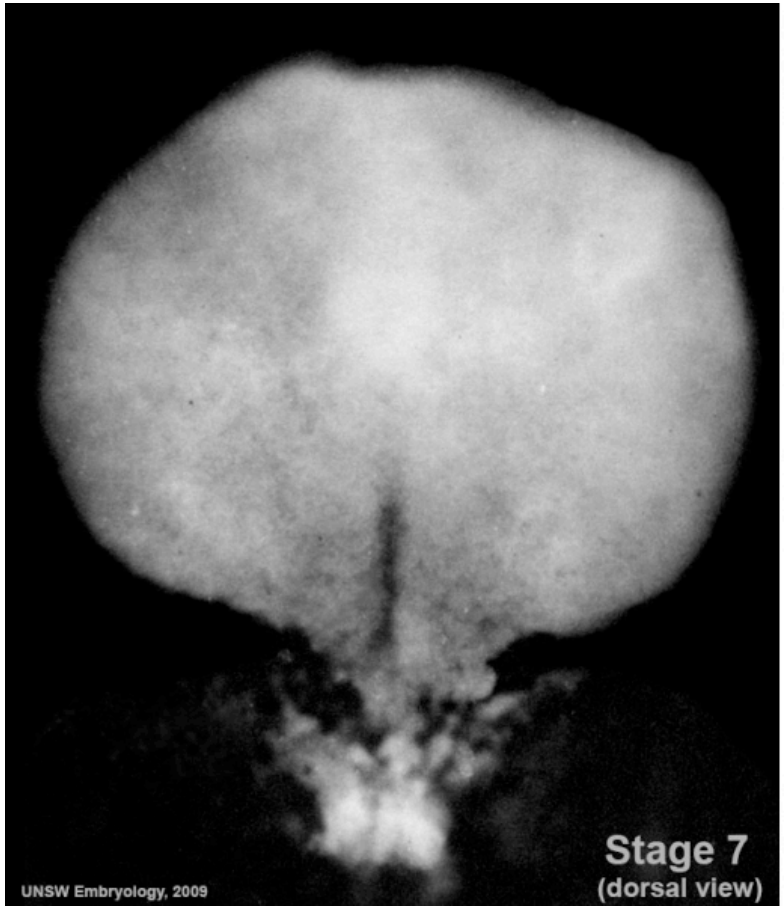

Neurulation

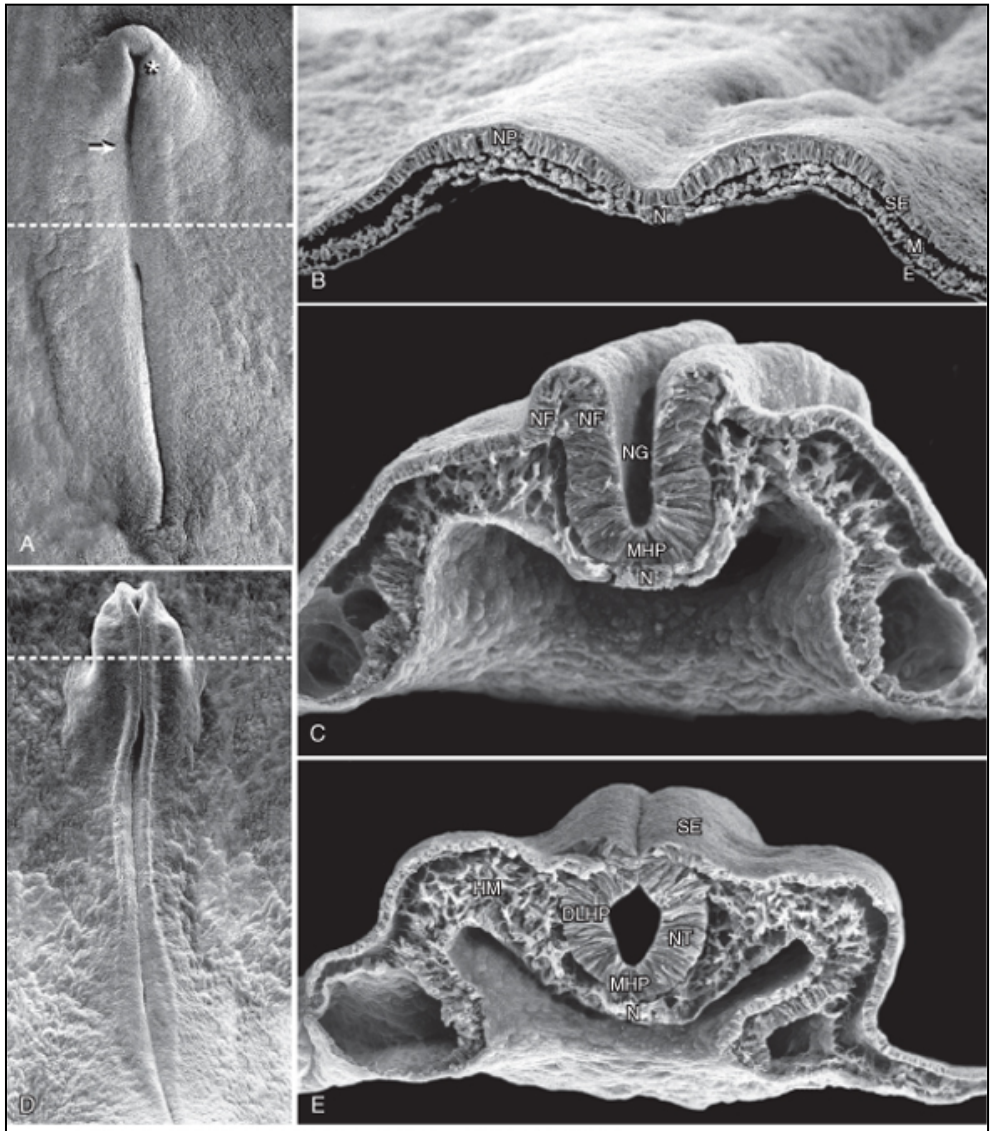

Neurulation

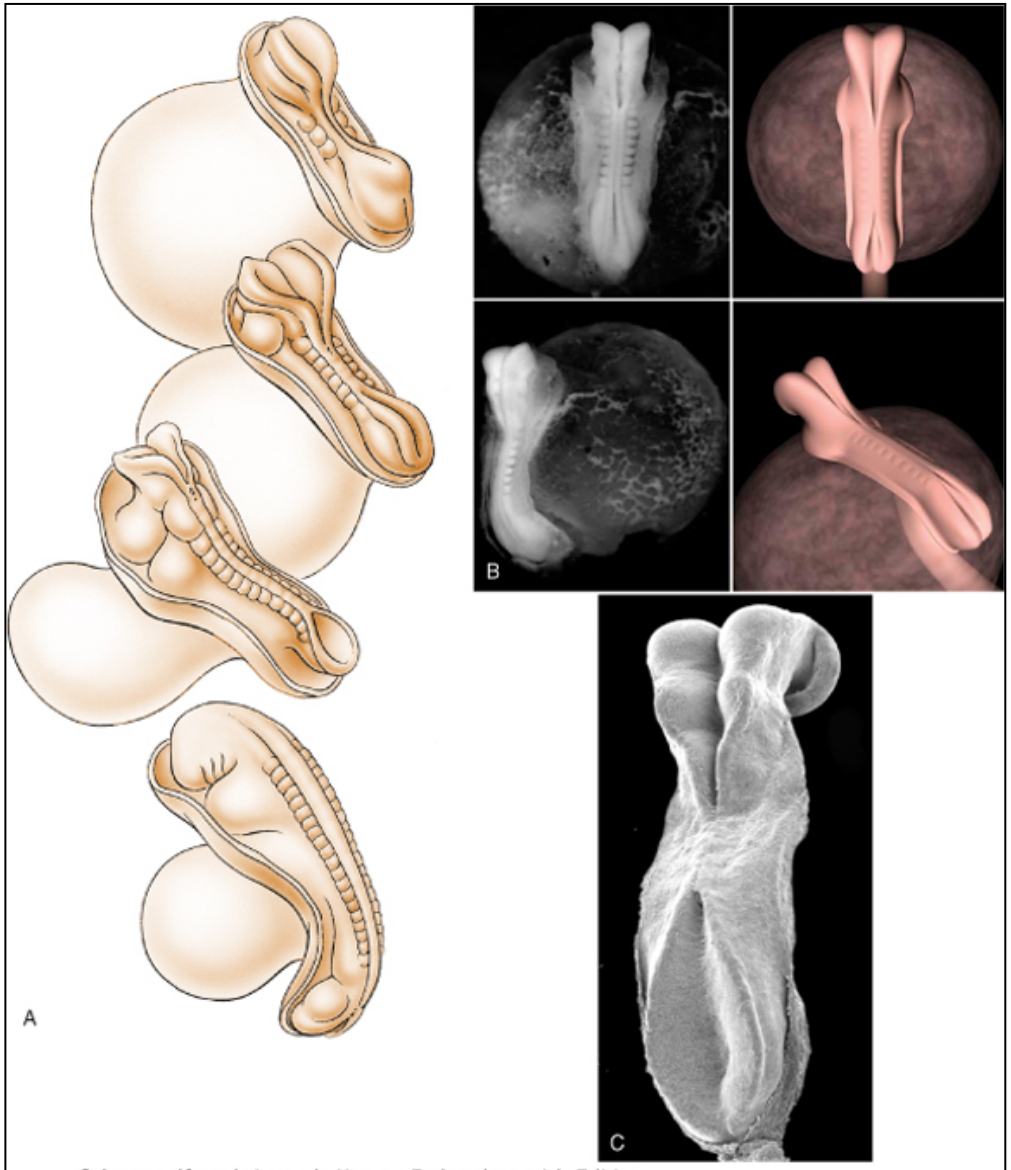

Schoenwolf et al: Larsen's Human Embryology, 4th Edition.

Neurulation

Neurulation

Secondary neurulation

Closure of caudal neuropore completes neurulation
Secondary neurulation occurs posteriorly of node
Condensation of tail bud cells into medullary cord
Cavitation
Lumen merges with neural canal

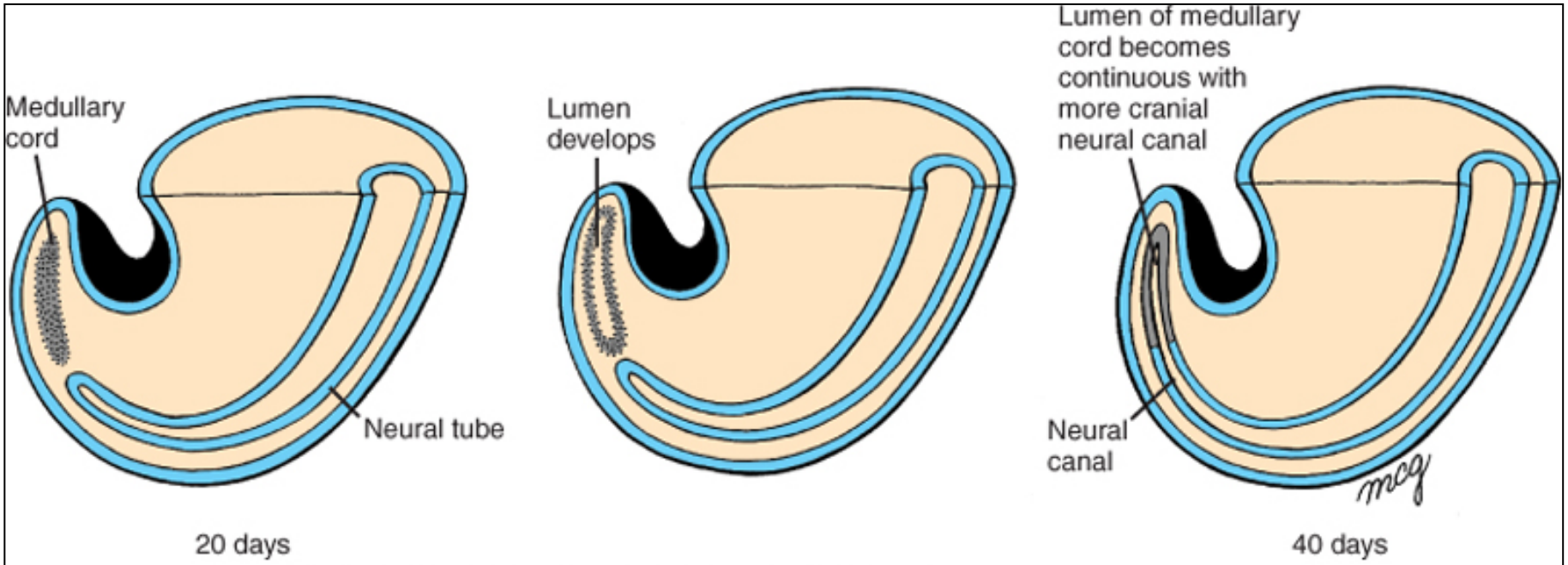

Neurulation

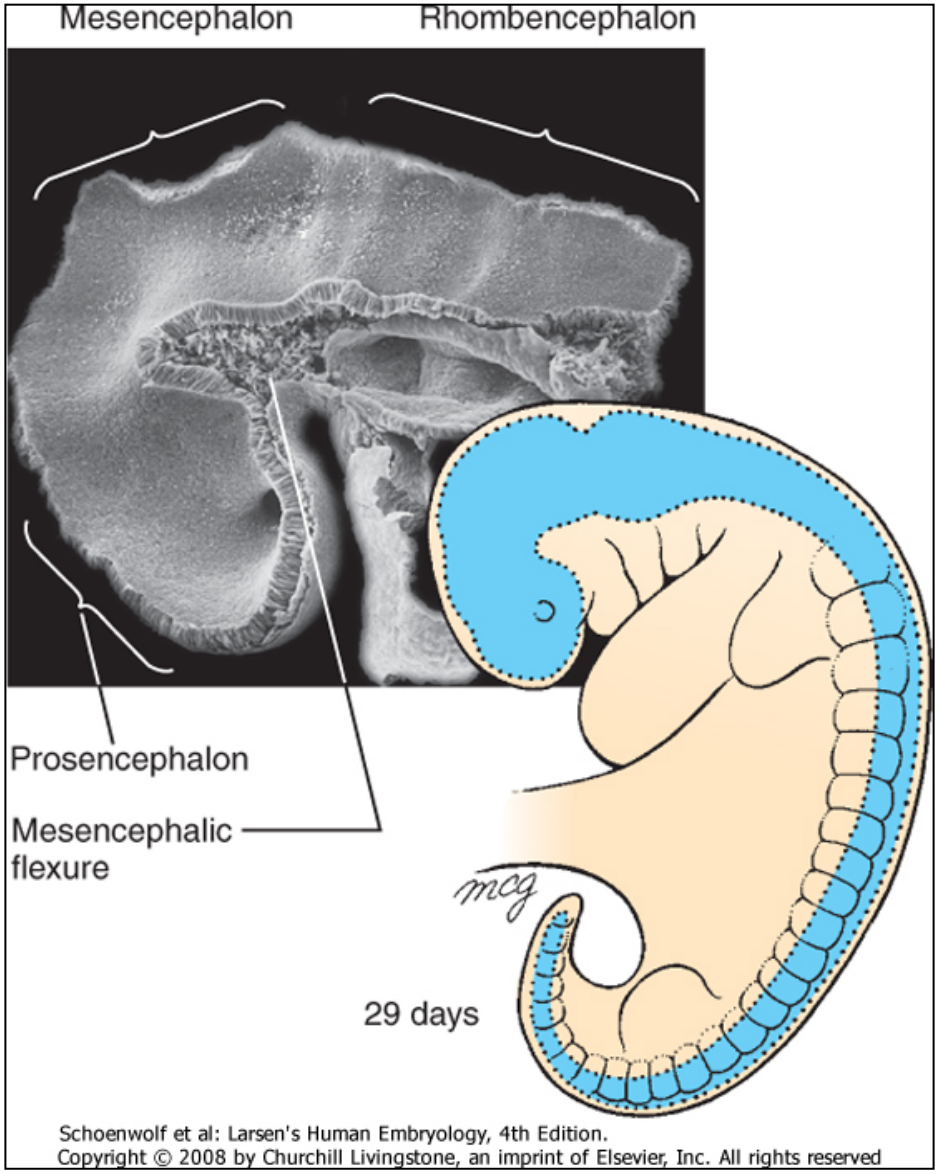

Early development of the CNS

3 primary brain vesicles
2 flexures

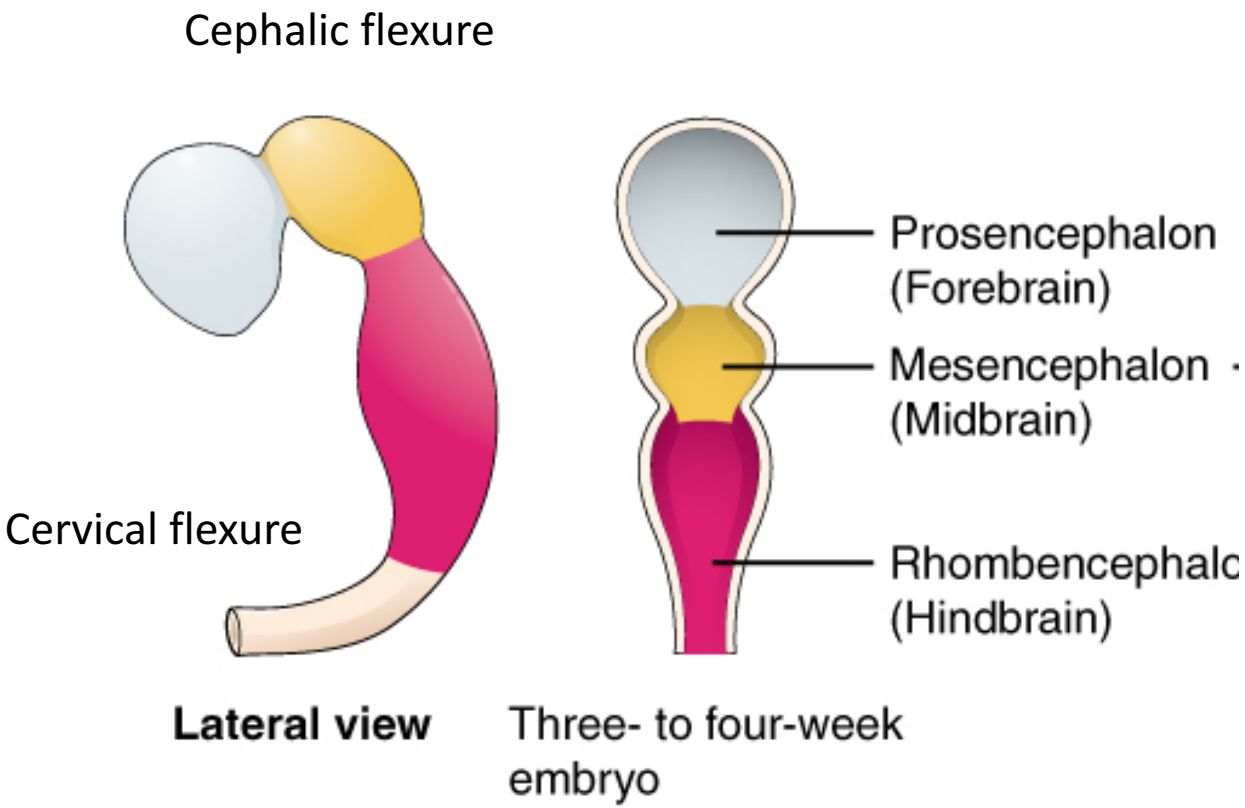

(a)

Early development of the CNS

5 secondary brain vesicles
3 flexures

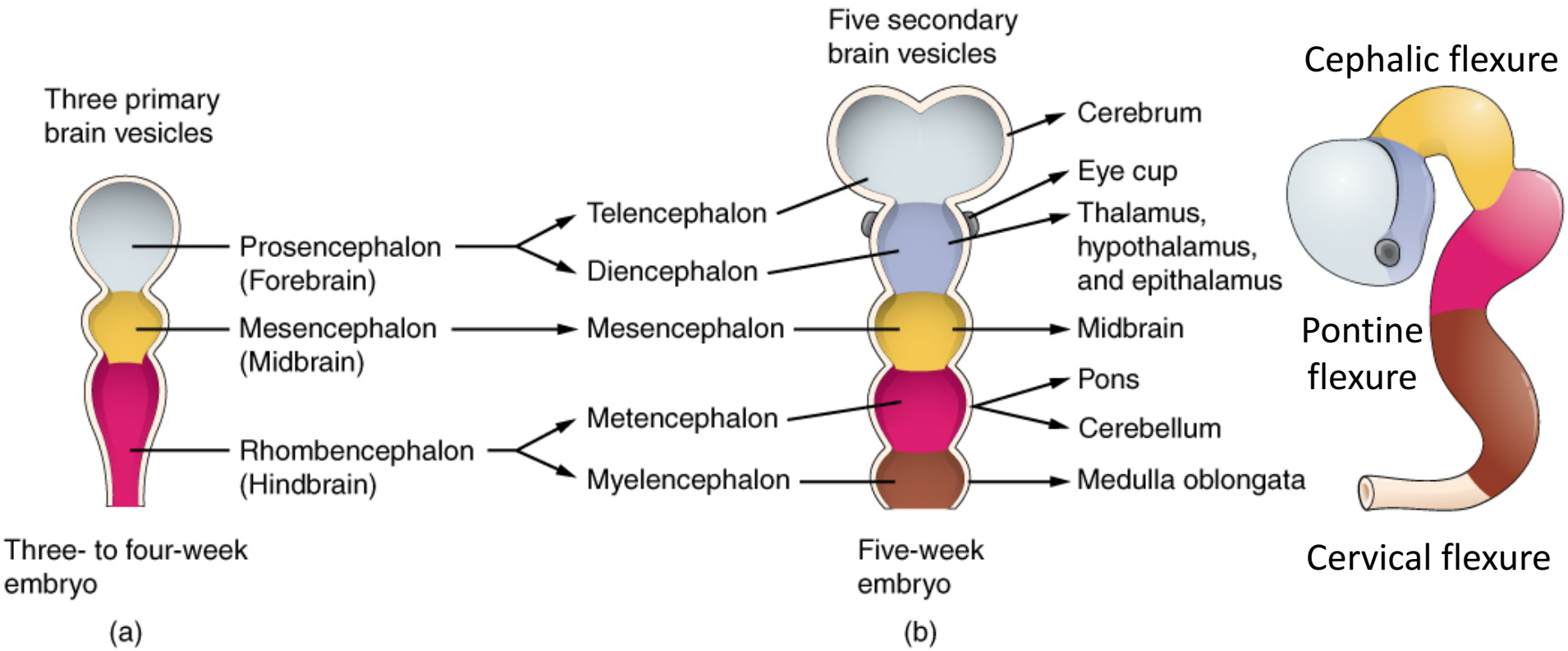

Early development of the CNS

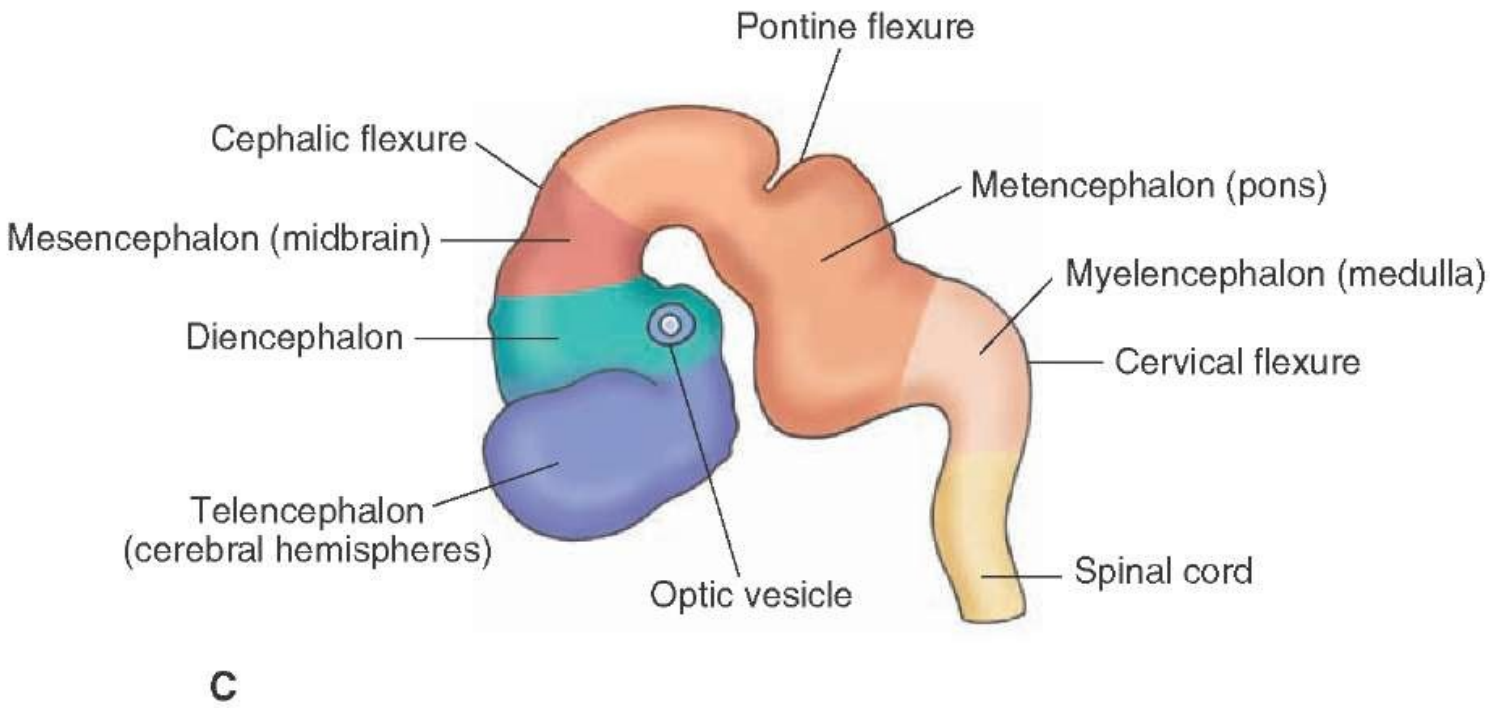

5-week embryo

Early development of the CNS

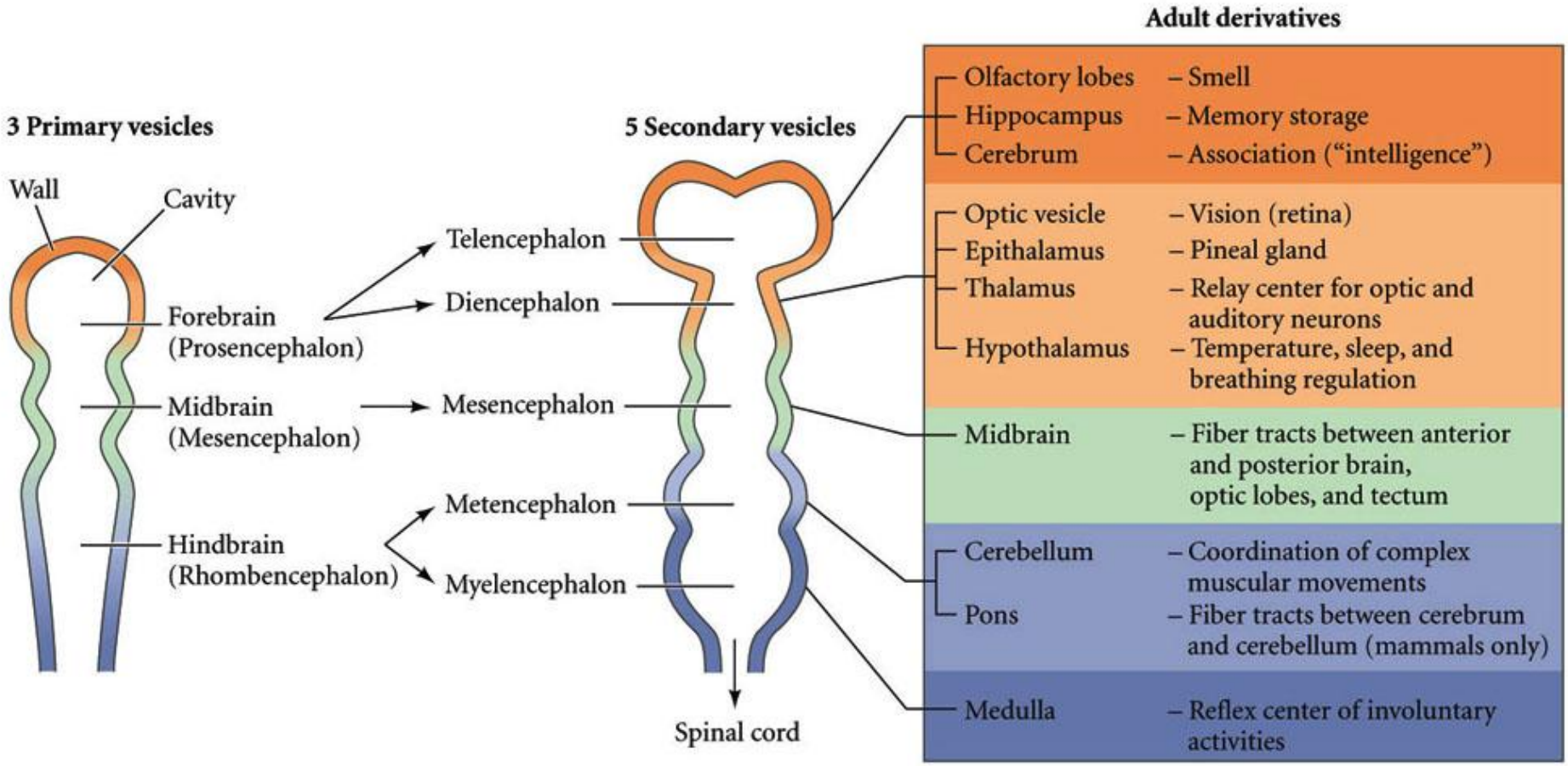

Neurulation

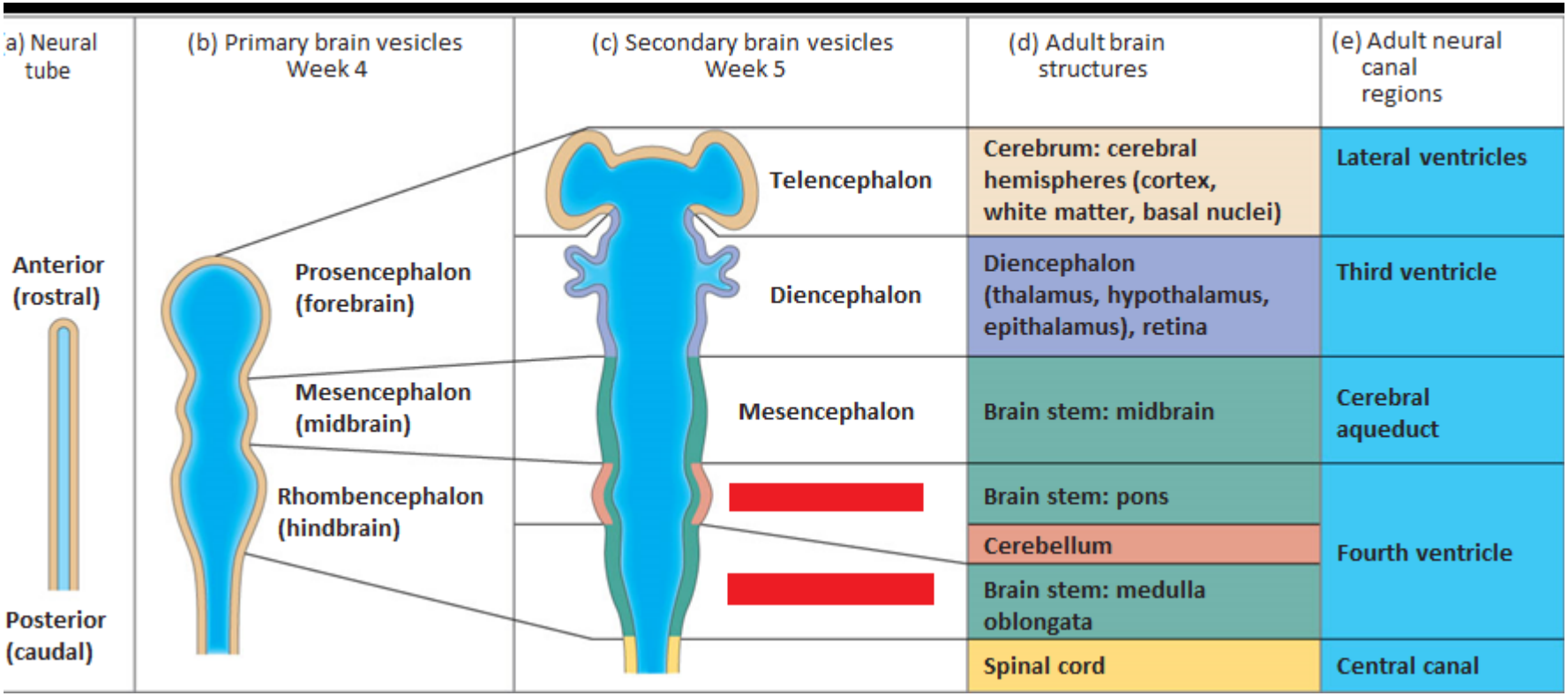

Early development of the CNS

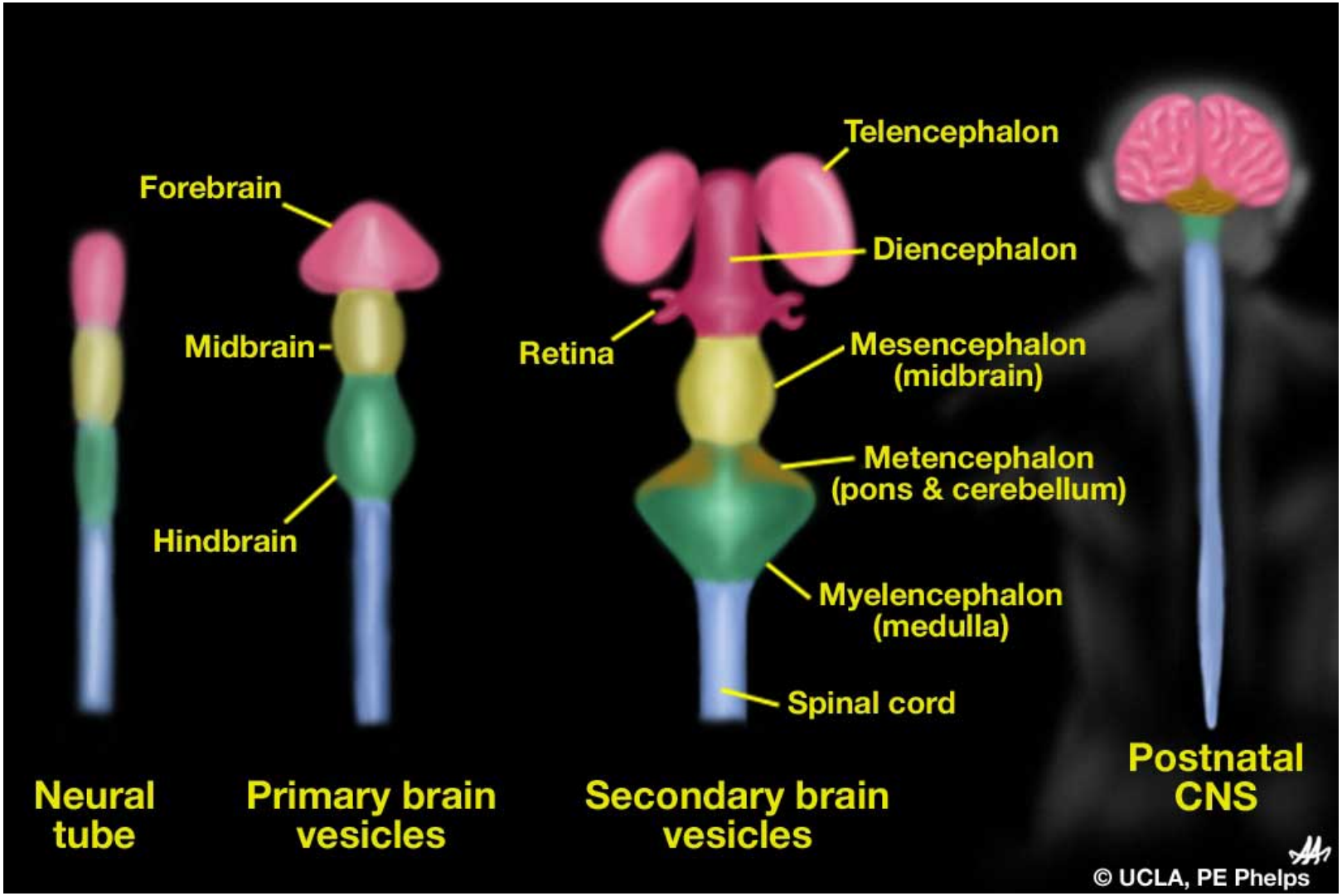

Brain Ventricles

Amniotic fluid -> Cerebrospinal Fluid
Continuous with central canal of neural tube
CSF is produced by choroid plexus
Hydrocephalus

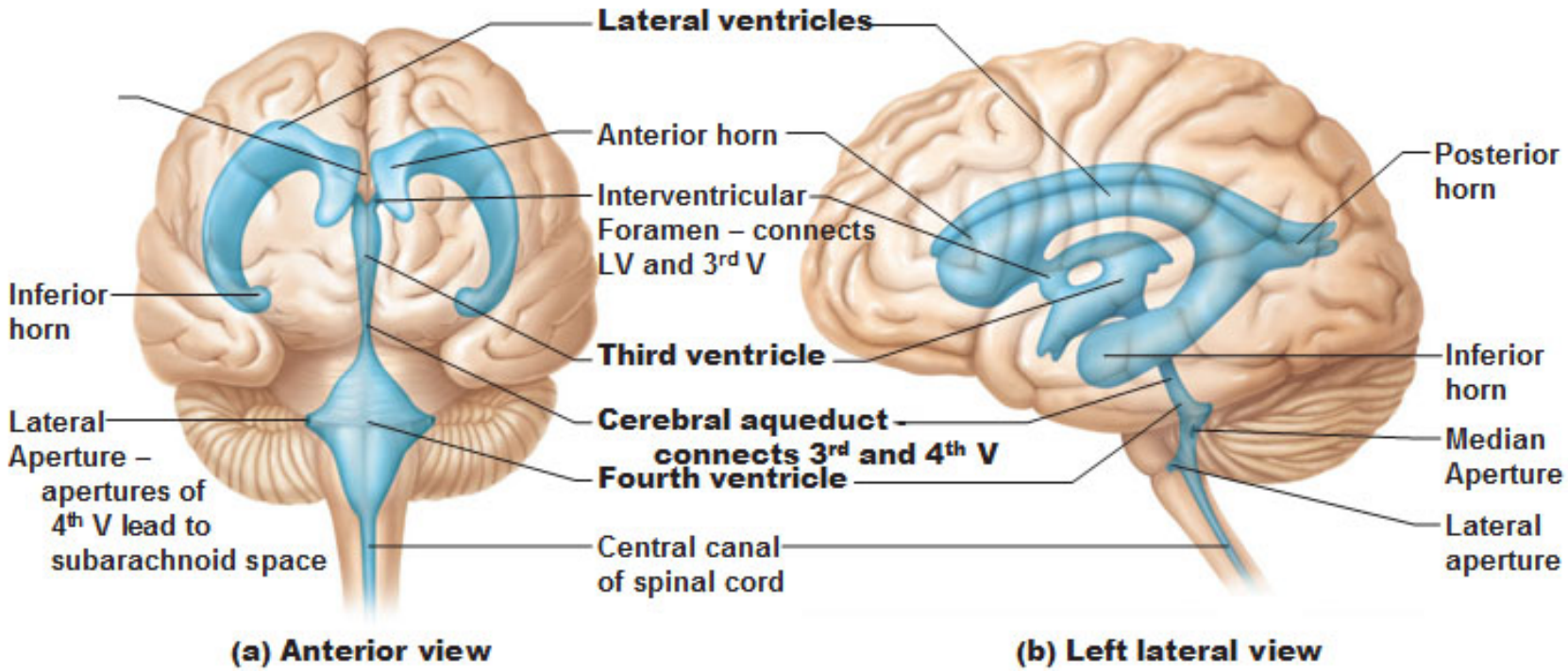

Spinal Cord Axes

Dorsoventral axis

Dorsal horns: interneurons receiving sensory input
Ventral horns: motor neurons

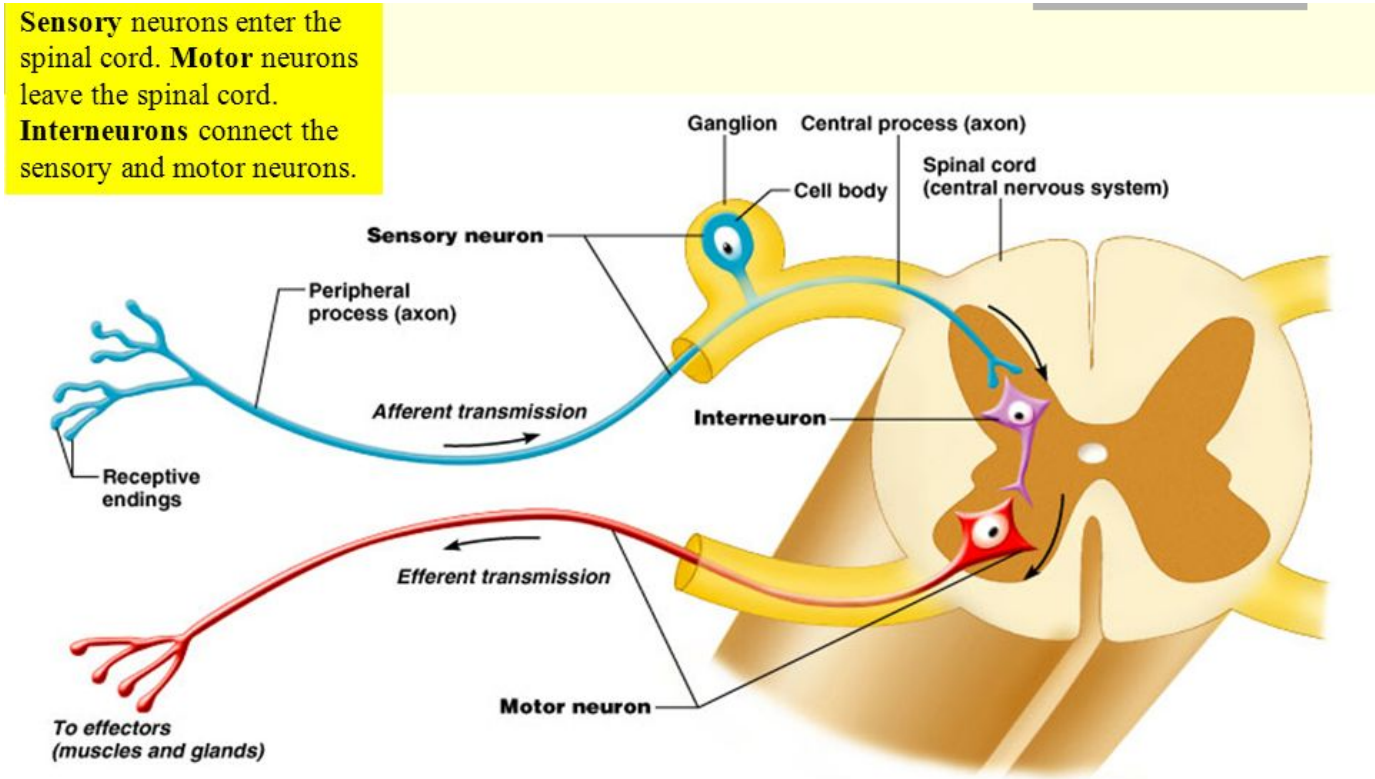

Spinal Cord Axes

Dorsoventral axis

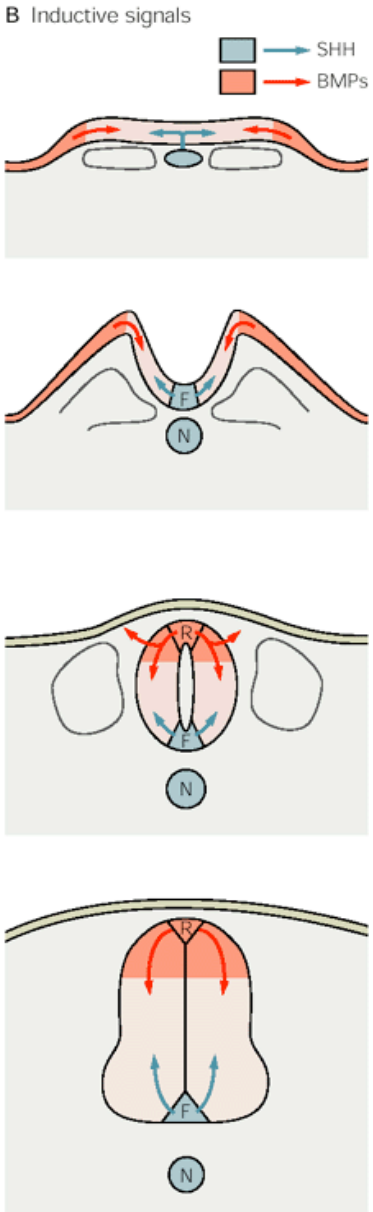

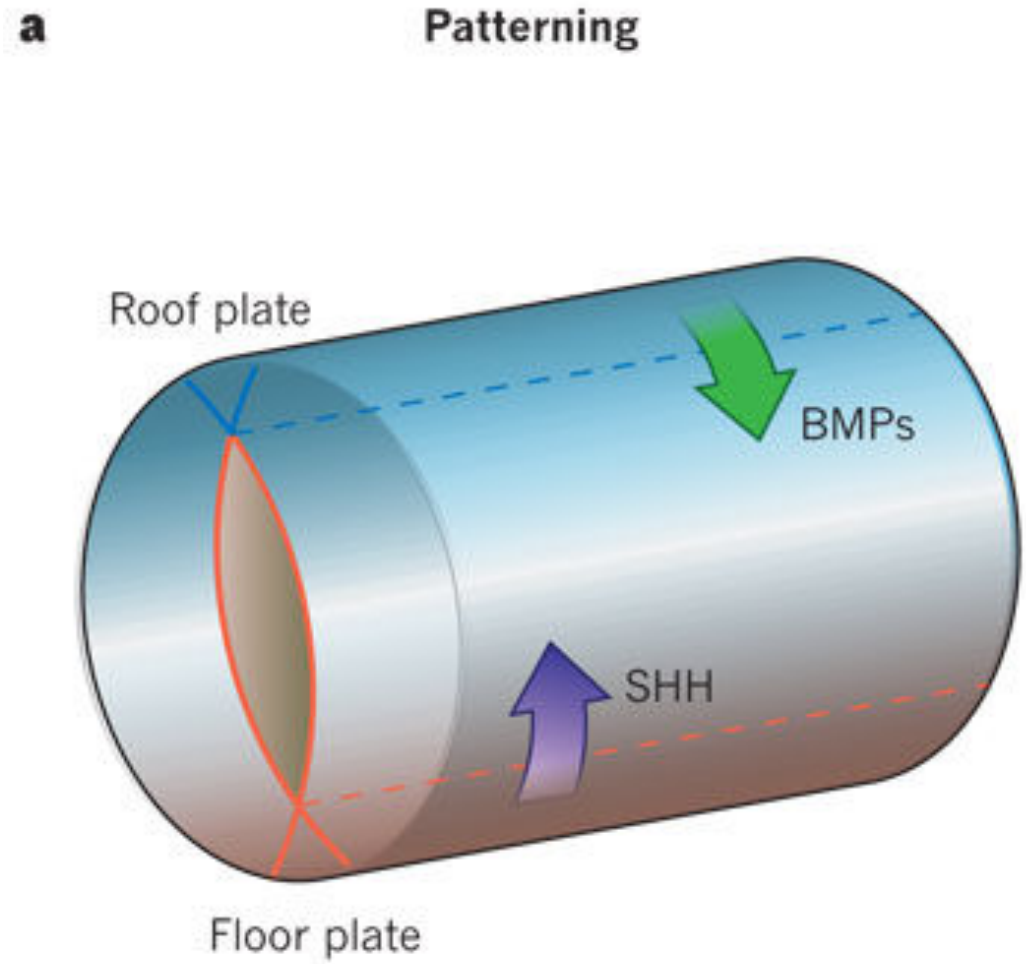

Spinal Cord Axes

Anteroposterior axis

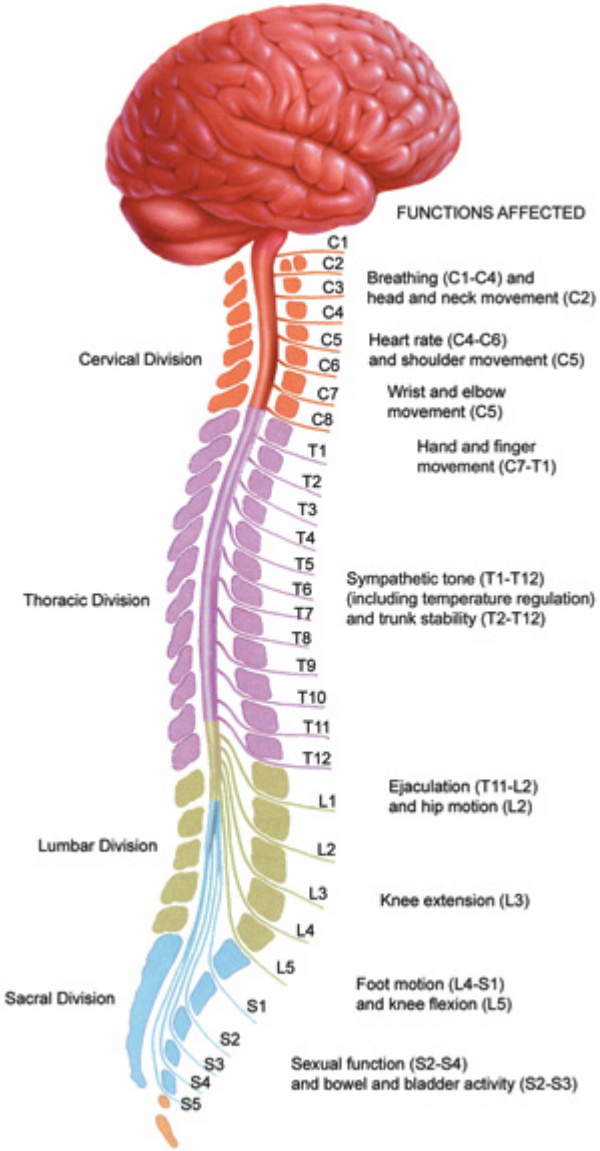

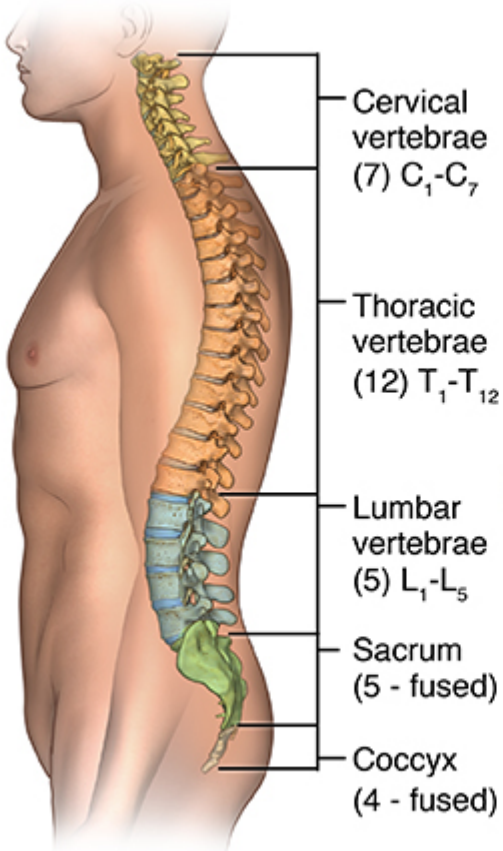

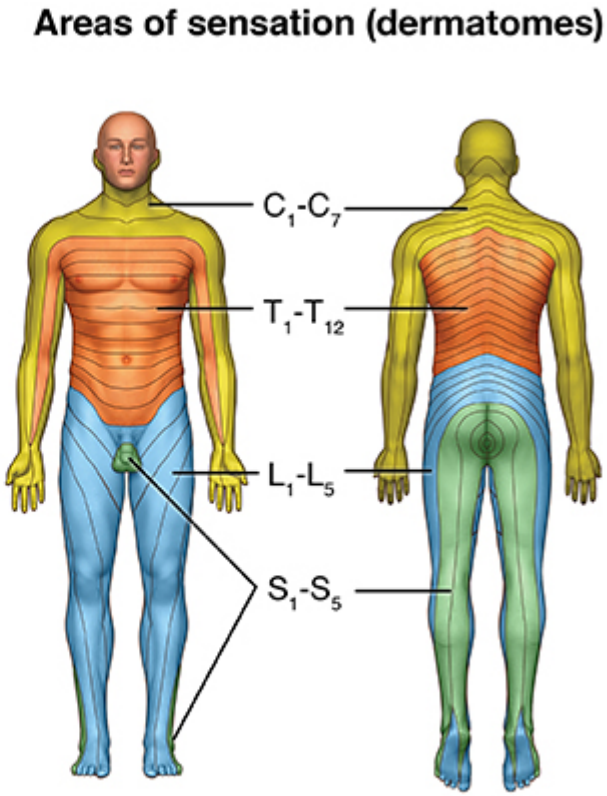

Spinal Cord Axes

Anteroposterior axis

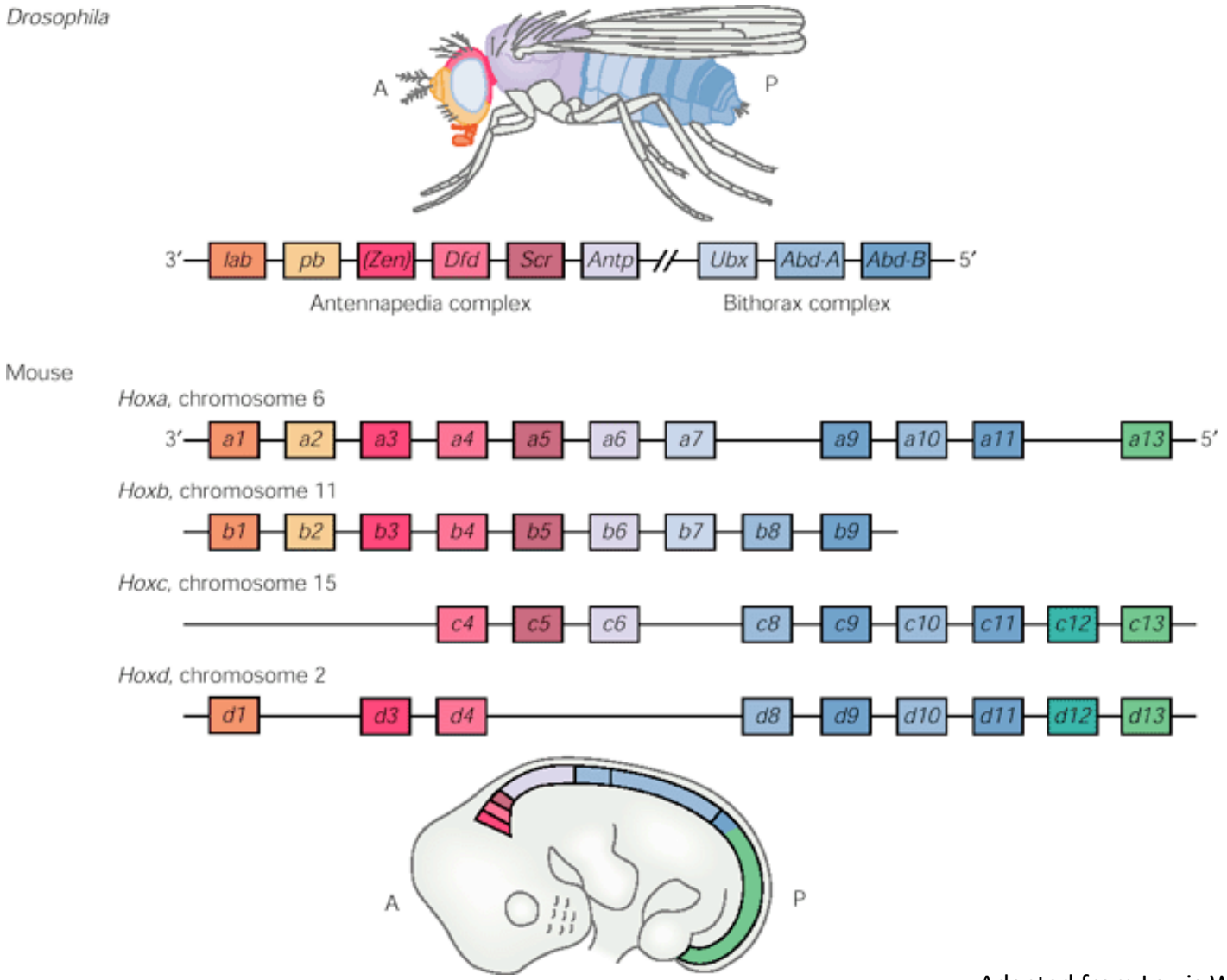

Adapted from Lewis Wolpert et al., 1998

Spinal Cord Axes

Anteroposterior axis

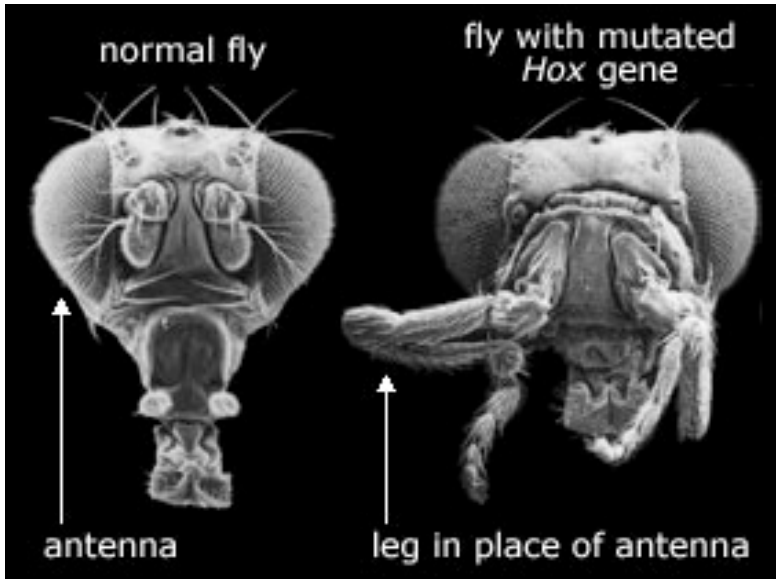

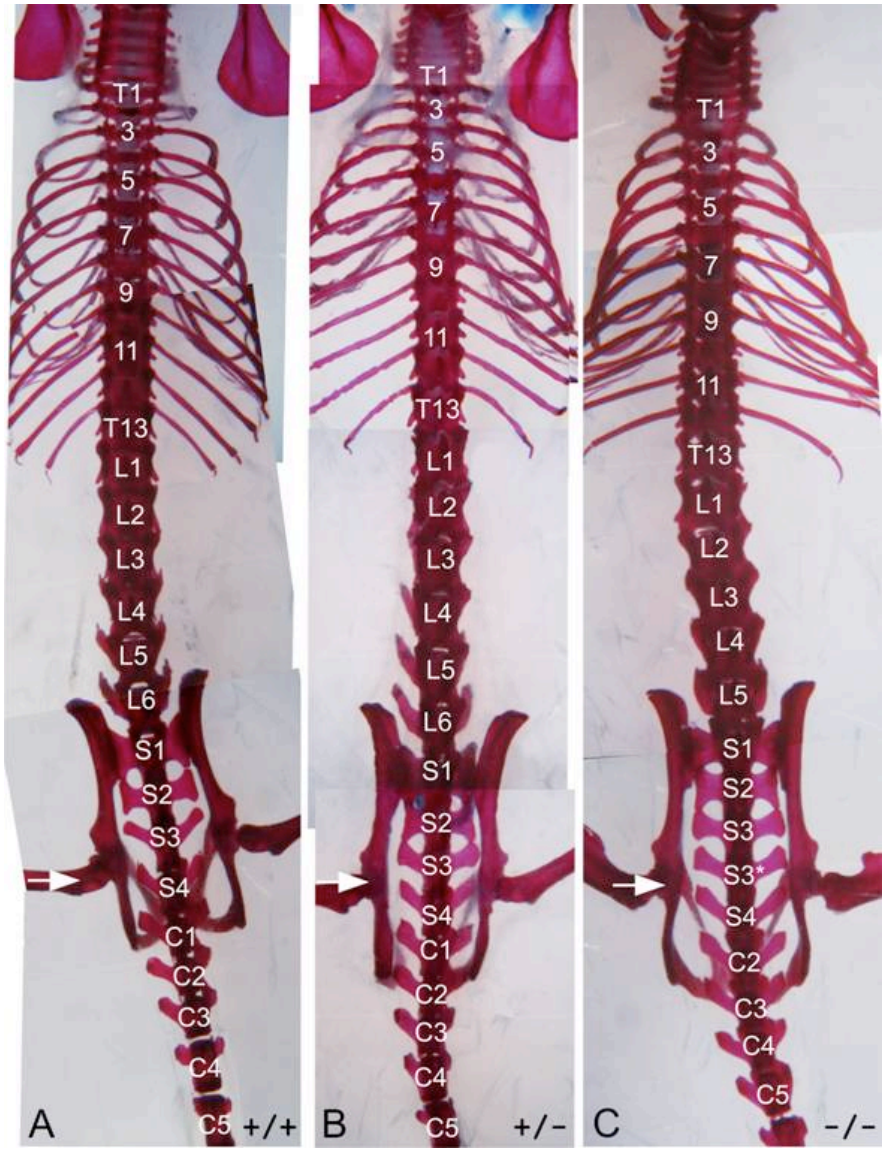

Hostikka et al., 2009

Cytodifferentation of the Neural Tube

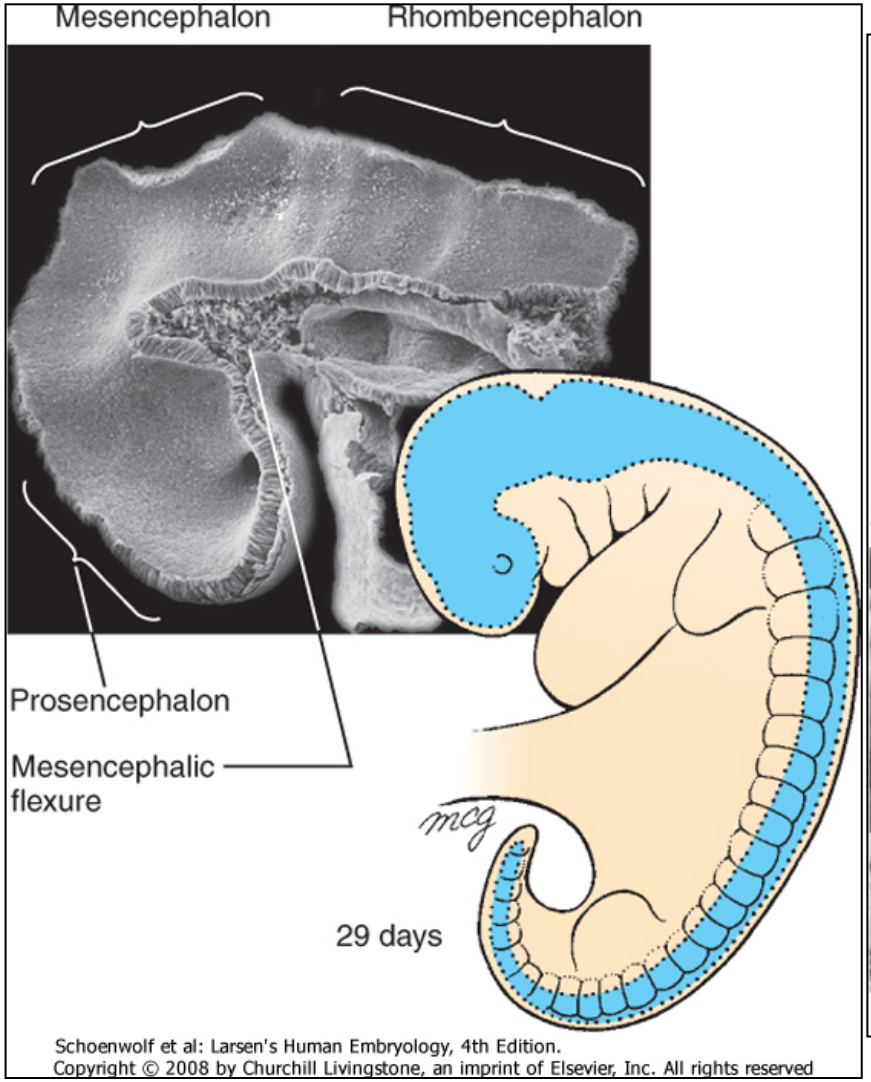

Schoenwolf et al: Larsen's Human Embryology, 4th Edition.

Time

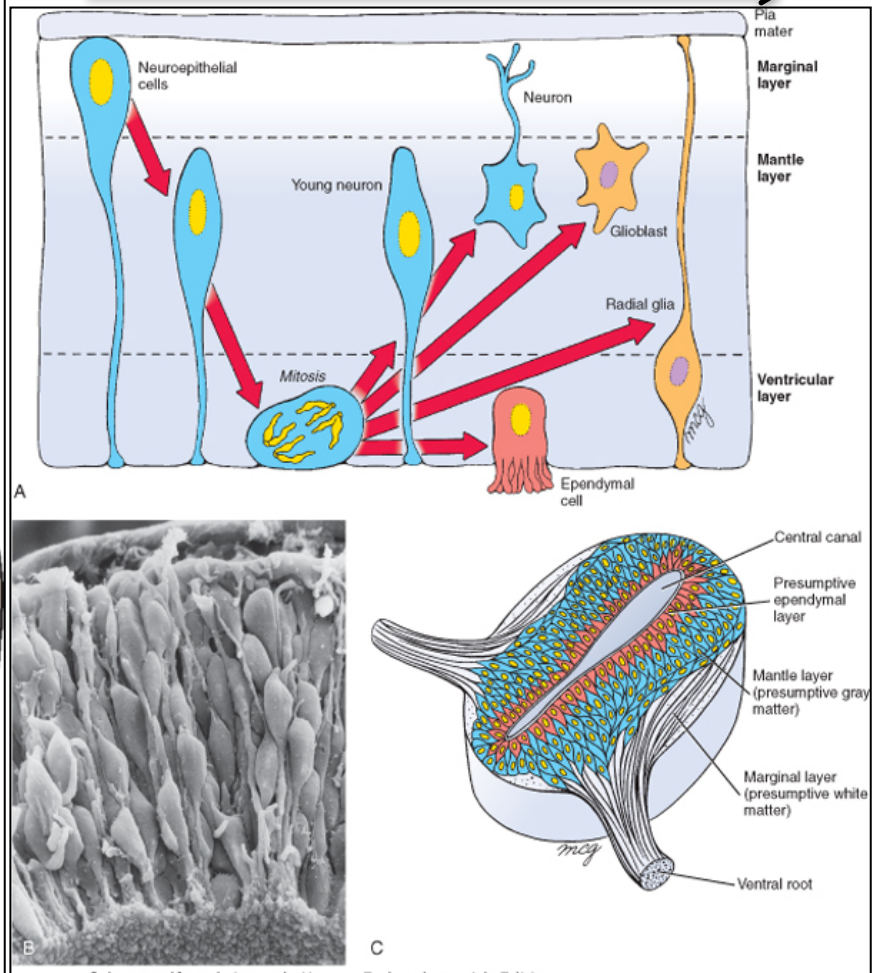

Schoenwolf et al: Larsen's Human Embryology, 4th Edition.

Neural Crest Development



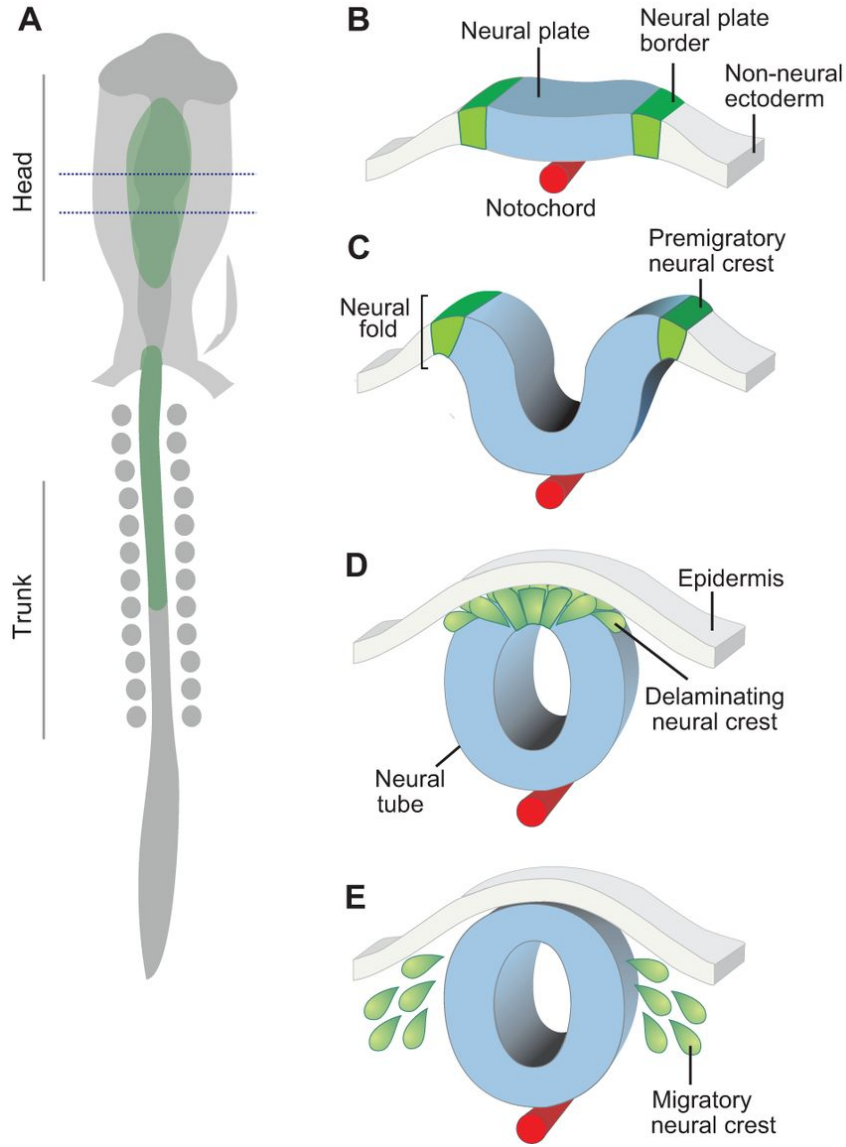

Neural Crest Development

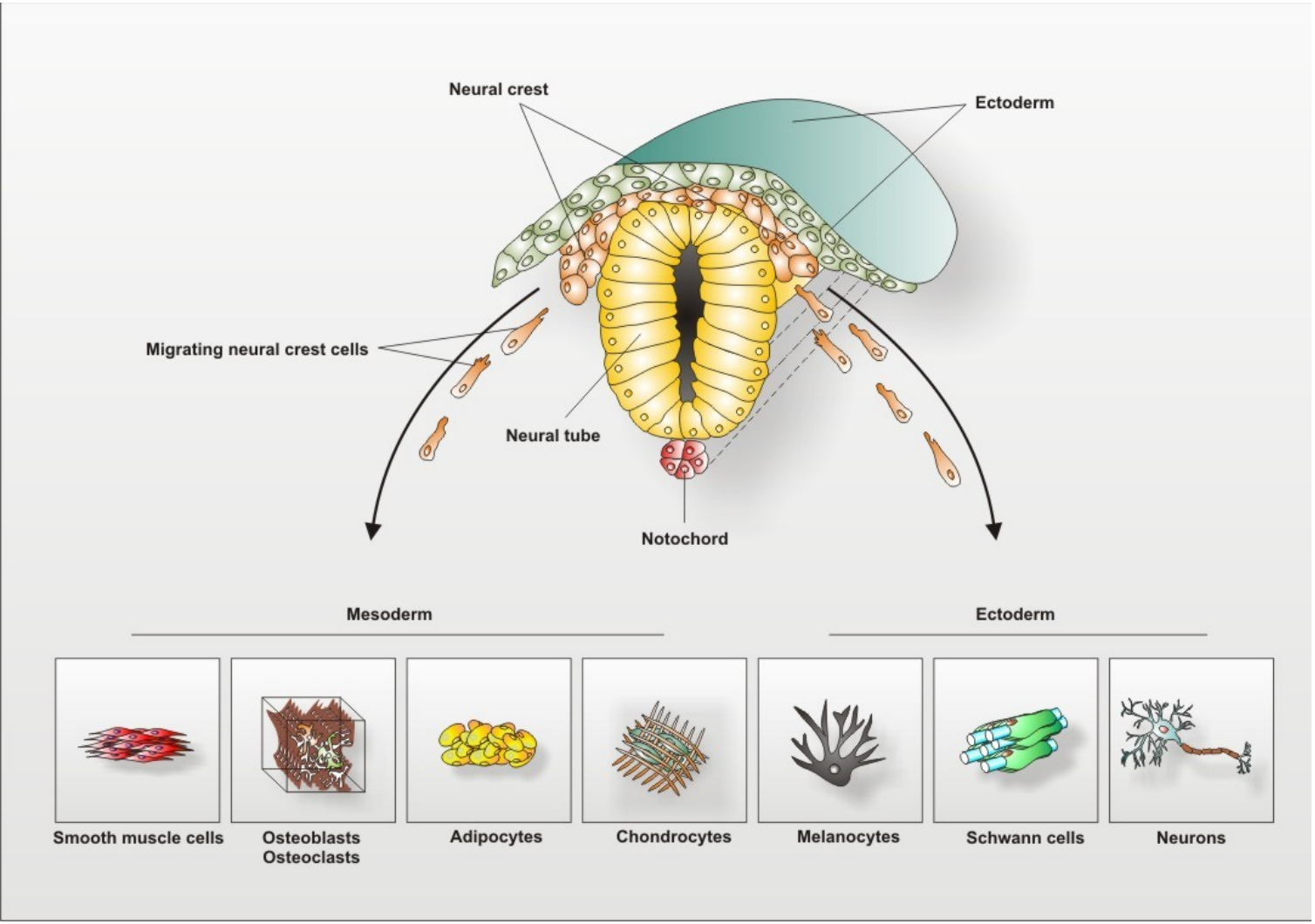

F Neural crest derivatives

Mesenchymal cells
- Chondroblasts/chondrocytes
- Osteoblasts/osteocytes
- Fibroblasts
- Odontoblasts
- Cardiac mesenchyme
- Myoblasts
- Adipocytes

Neuronal cells
- Sensory neurons
- Cholinergic neurons
- Adrenergic neurons
- Satellite cells
- Schwann cells
- Glial cells

Secretory cells
- Chromaffin cells
- Parafollicular cells
- Calcitonin-producing cells

Pigmented cells
- Melanocytes

Neural Crest Development
4 functional domains and lineages

Cranial neural crest:
Cranial mesenchyme, facial skeleton,
cranial nerve ganglia

Cardiac neural crest:
Melanocytes, cartilage, connective tissue
and neurons of some pharyngeal arches,
Contributes to formation of regions of the heart

Trunk neural crest:
Melanocytes, dorsal root ganglia, sympathetic ganglia,
adrenal medulla,
nerves surrounding aorta

Vagal and Sacral neural crest:
Melanocytes, ganglia of the enteric nervous system
Parasympathetic ganglia

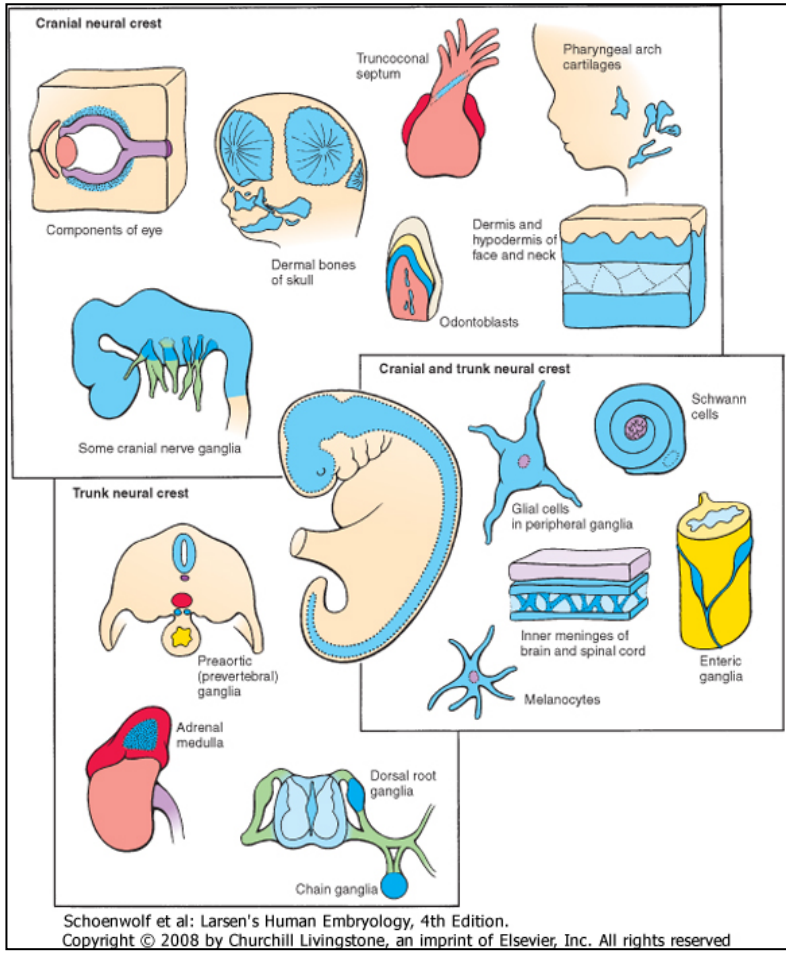

Schoenwolf et al: Larsen's Human Embryology, 4th Edition.

Neural Crest Development

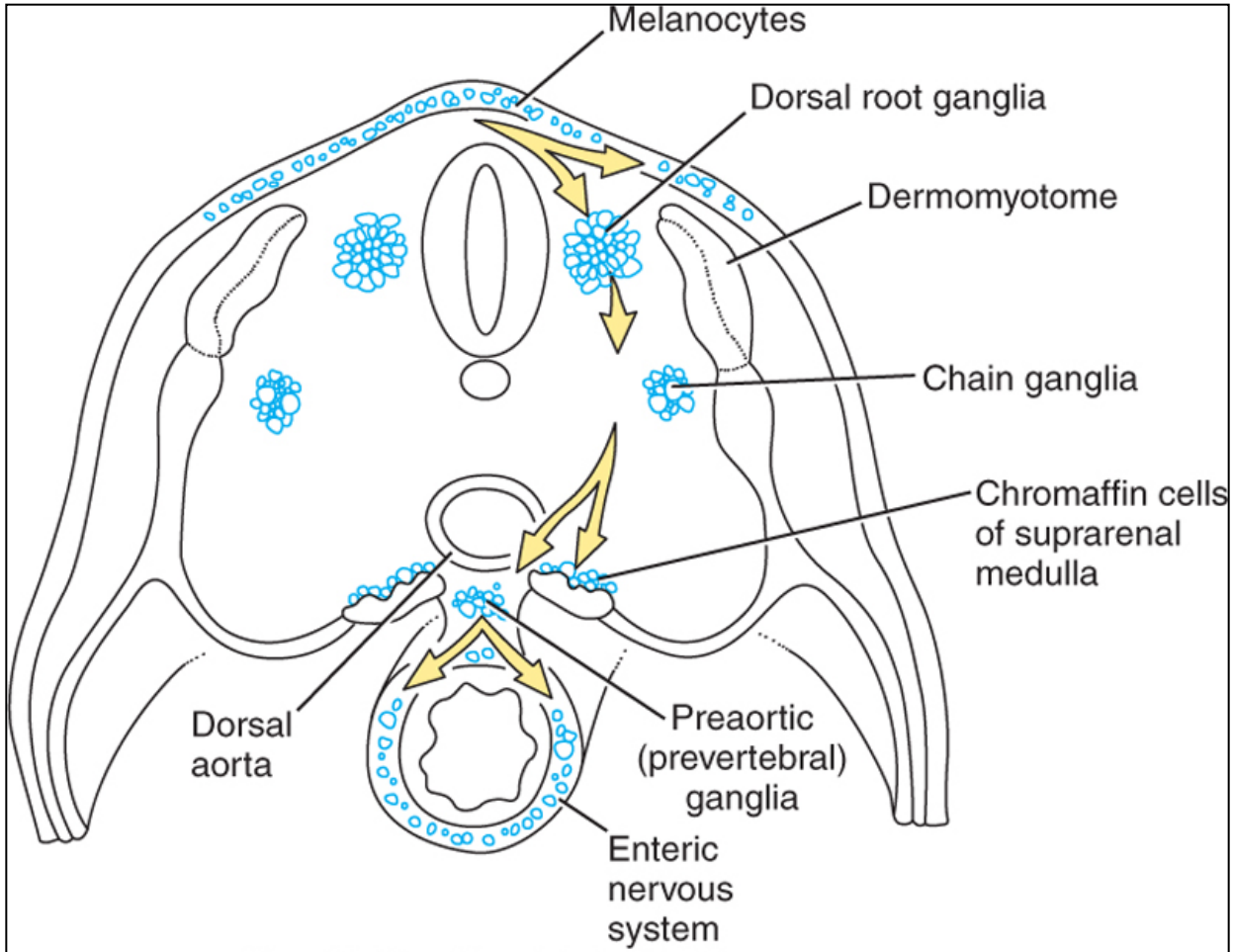

Neural Crest Development

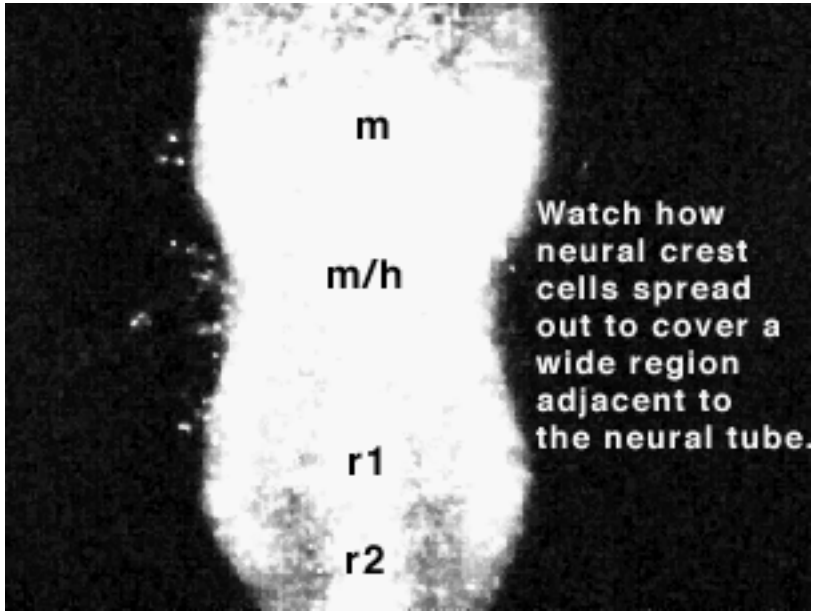

Epidermal development
Lateral surface ectoderm



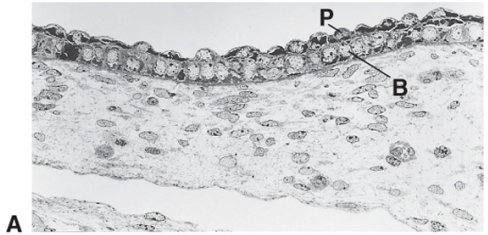

Adult

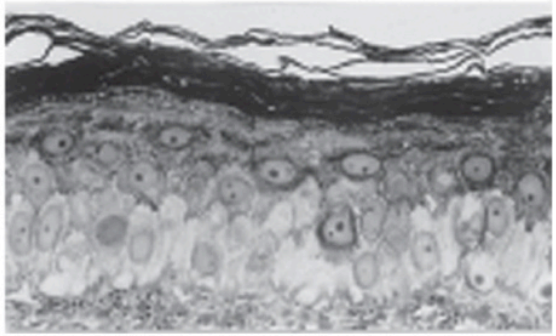

Interfollicular epidermis (surface epithelium)

Epidermal Appendages:

- Hair follicles
- Glands (sebaceous, sweat, apocrine)
- Mammary glands
- Nails
- Teeth

Ectodermal placodes

Specialized ectodermal thickenings in cranial region
Contribute to sensory structures, teeth and pituitary

Otic placodes
Olfactory (Nasal) placodes
Optic (Lens) placodes
Adenohypophyseal placode
Profundal/trigeminal placodes

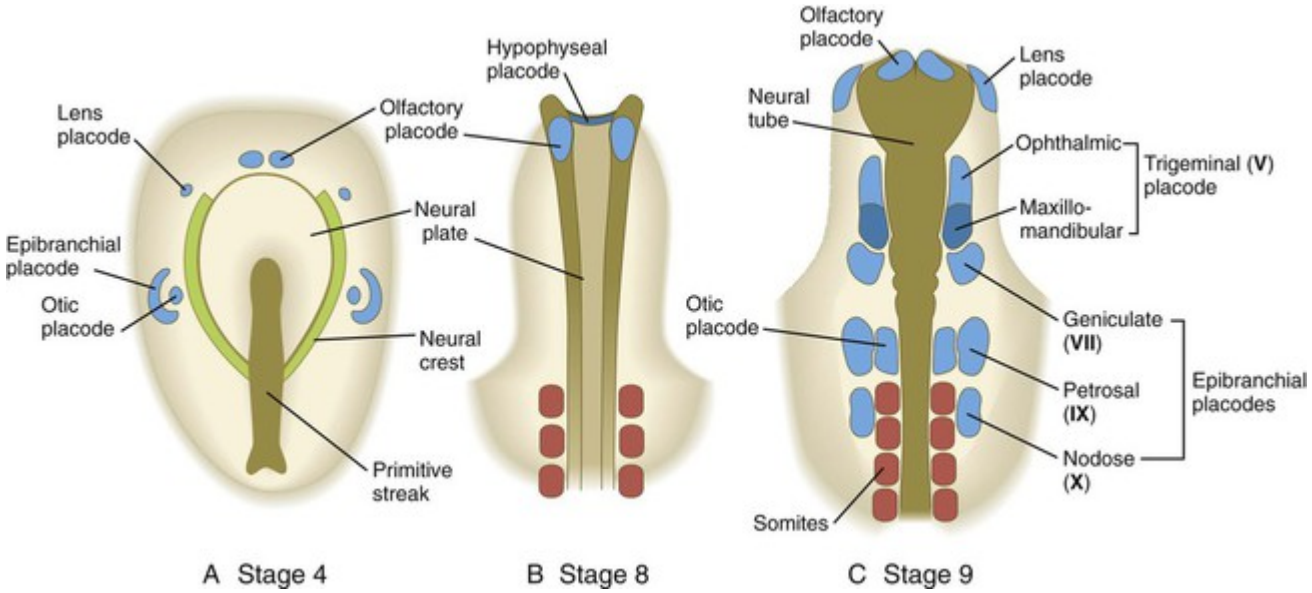

Ectodermal placodes

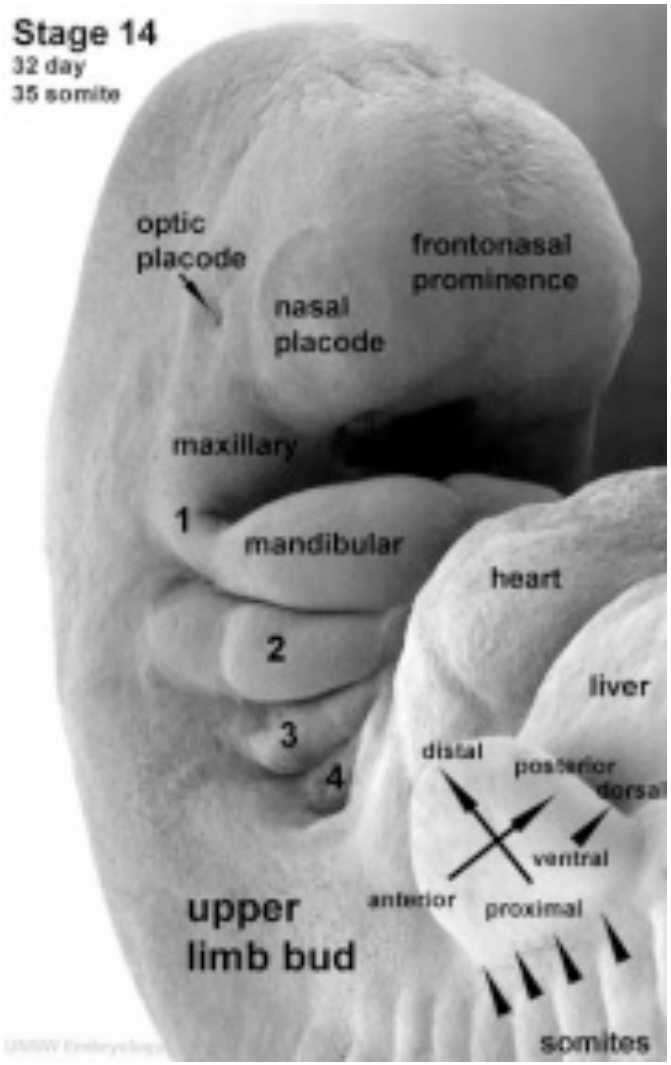

Otic placodes
Olfactory (Nasal) placodes
Optic (Lens) placodes
Adenohypophyseal placode
Profundal/trigeminal placodes

Neural Tube Defects

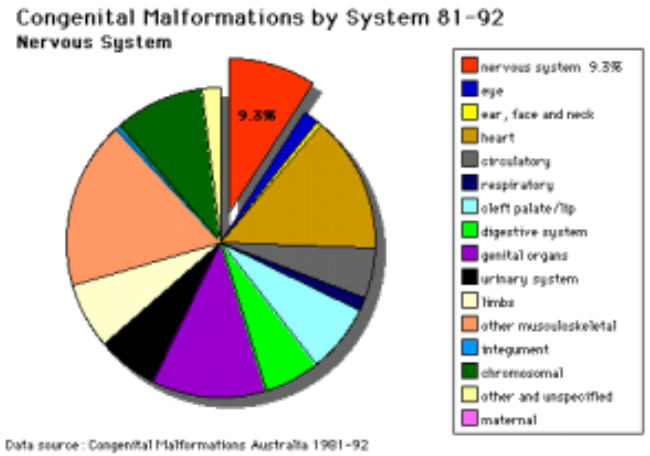

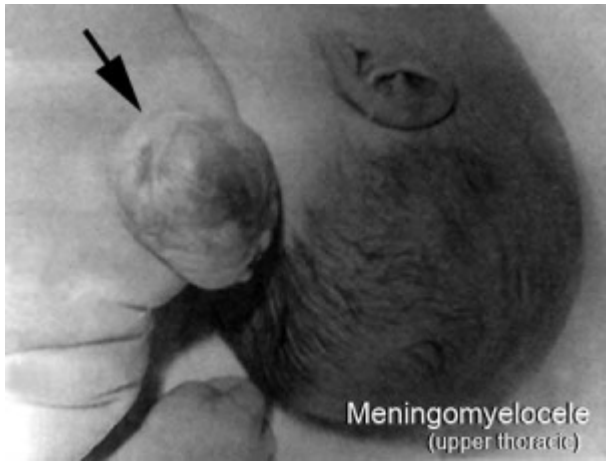

Dysraphism:
Spina bifida and anencephaly

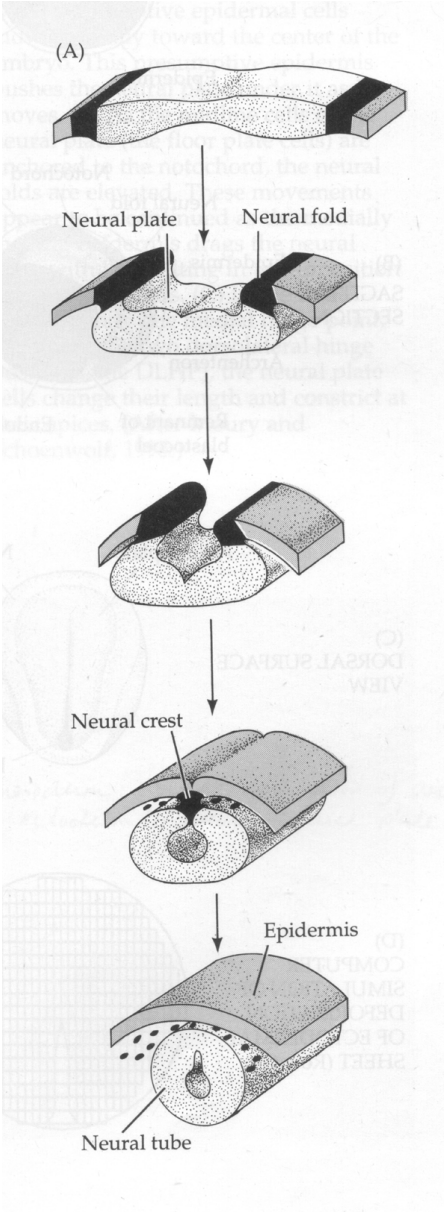

Folate protects against NTDs

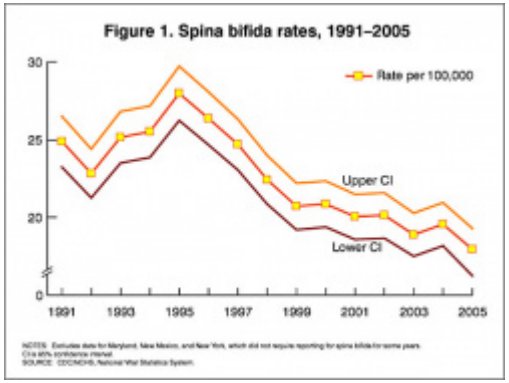

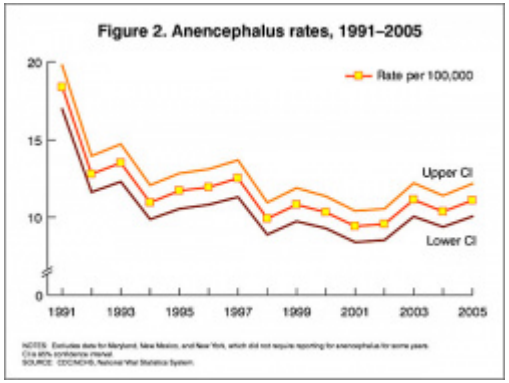

Neural Tube Defects
Holoprosencephaly

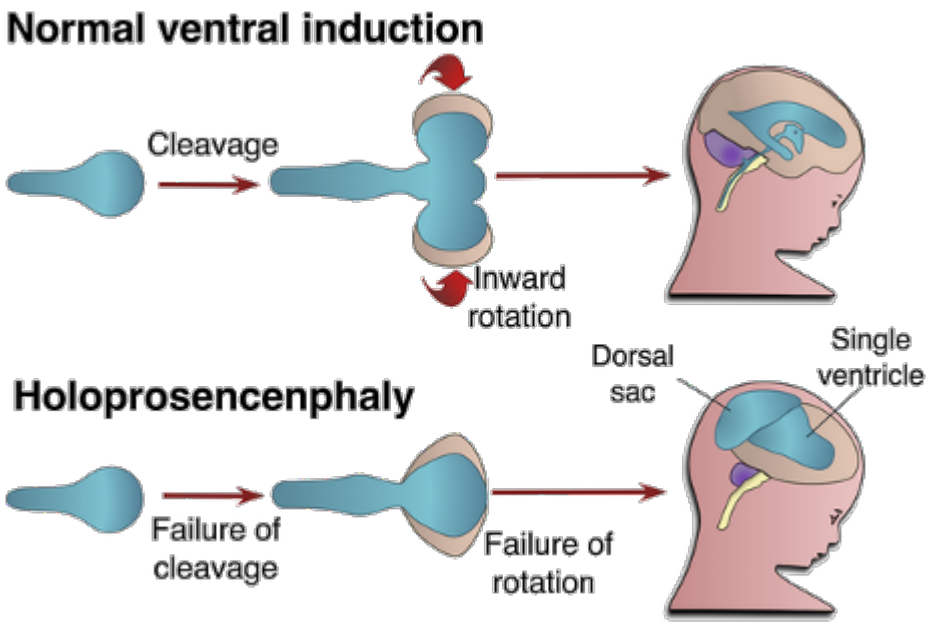

Neural Tube Defects

Holoprosencephaly

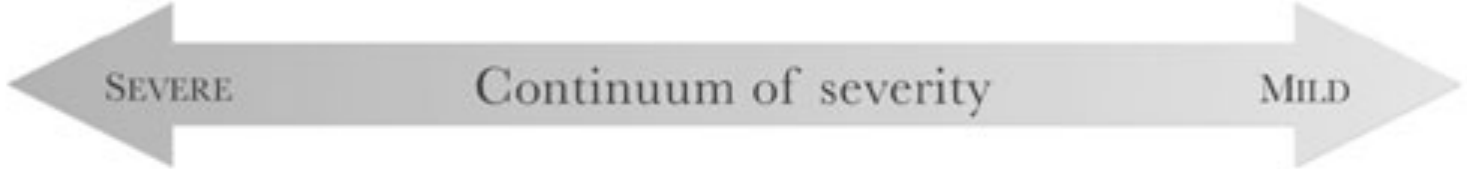

Lecture overview
Early Development of the Ectoderm

Gastrulation and Embryonic Folding

Neurulation

Early Development of the Nervous System

Neural Crest

Epidermis Development

Ectodermal placodes

Neural Tube Defects

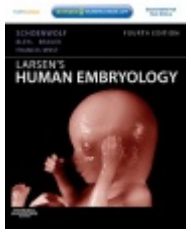

Resources:
http://php.med.unsw.edu.au/embryology/
Larsen's Human Embryology
The Developing Human: Clinically Oriented Embryology

Dr Annemiek Beverdam – School of Medical Sciences, UNSW
Wallace Wurth Building Room 234 – A.Beverdam@unsw.edu.au